CT / White paper

Advancing Lung Parenchyma CT imaging: Clinical Impact of Precise IQ Engine (PIQE) 1024 Matrix

powered by Altivity



Dr. Russell Bull
Royal Bournemouth Hospital, UK



Dr. Tae Iwasawa
Kanagawa Cardiovascular & Respiratory Center, Japan



Prof. Mickaël Ohana MD, PhD
Nouvel Hôpital Civil, Strasbourg University Hospital, France



Prof. Patrik Rogalla BS, MD, PhD, MBA
University Health Network, Toronto, Canada

Introduction

Accurate diagnosis of various lung diseases, including interstitial lung disease (ILD), tumors, cystic lung disease, infections, small airways disease, and bronchiectasis, heavily relies on high-quality medical imaging. Computed Tomography (CT) is the preferred imaging modality over conventional X-ray radiography for evaluating lung pathology. This preference stems from CT's ability to generate multi-planar images and simultaneously visualize lung parenchyma, bone, and soft tissues without the superimposition of structures inherent to X-ray. While the in-plane spatial resolution of CT may be lower than that of conventional X-ray, the absence of superimposed structures makes CT the modality of choice for diagnosing the vast majority of chest and lung diseases. For the detection and classification of interstitial lung diseases, specifically, thin sections (less than 1.5 mm thickness) are recommended to improve spatial resolution and minimize partial volume effects[1,2]. Furthermore, a high-resolution reconstruction algorithm is crucial for optimally visualizing the fine structures within the lung parenchyma. Historically, achieving this level of detail in CT has presented a trade-off: thinner slices inevitably lead to noisier images. Therefore, advanced noise-mitigating technologies are paramount to ensure diagnostic image quality without increasing the radiation dose to patients[3].

To overcome this challenge, Canon has developed a Super Resolution Deep Learning Reconstruction, Precise IQ Engine (PIQE), designed to maximize the resolution of the detector and deliver sharp images from standard CT acquisitions while maintaining low noise.

As with all Deep Learning, the key to maximizing performance lies in the training process.



Figure 1: PIQE Lung 1024 delivers excellent spatial resolution and reduced noise. Courtesy Prof Ohana, Strasbourg University Hospital, France

PIQE 1024 Matrix Training Principles

The training data were acquired using the Aquilion Precision's Ultra-High Resolution (UHR) mode (0.25 mm × 160), which can resolve anatomical detail as fine as 150 microns. These UHR datasets were reconstructed with AiCE Deep Learning Reconstruction (DLR), which implicitly incorporates the advanced modeling capabilities of Model-Based Iterative Reconstruction (MBIR). Importantly, raw UHR data can be down-sampled through a reconstruction algorithm to generate simulated Normal Resolution (NR) images, which have been shown to be equivalent to true NR images[PR1] . This approach enables both UHR and NR images to be produced from a single acquisition, with perfect spatial alignment between the two image sets, an ideal scenario for training neural networks. In this training process, the simulated NR images serve as inputs, while the corresponding UHR images act as the reference standard targets. The neural network thus learns to maximize the resolution potential of NR images while simultaneously reducing noise (Figure 2). Figure 3 illustrates a lung scan comparison between the Aquilion Precision (UHR-CT) and a follow-up scan performed with PIQE, demonstrating similar sharpness overall, with some differences evident in zoomed regions.

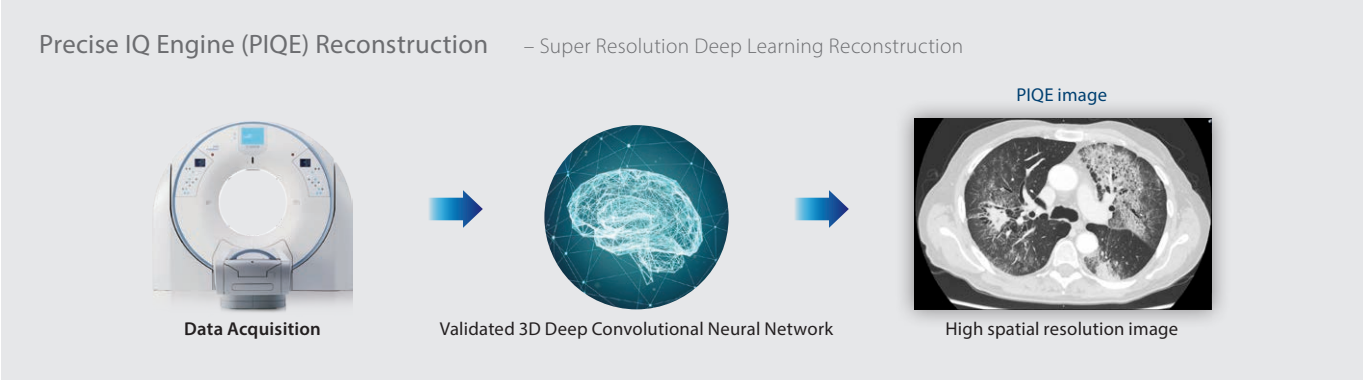

Figure 2: Training of PIQE network. Training data is prepared by down-sampling Precision UHR data. The network is trained using UHR data paired with down sampled, simulated NR data and actual UHR data. Once trained the network is validated and applied to the image reconstruction where it does not continue to learn.

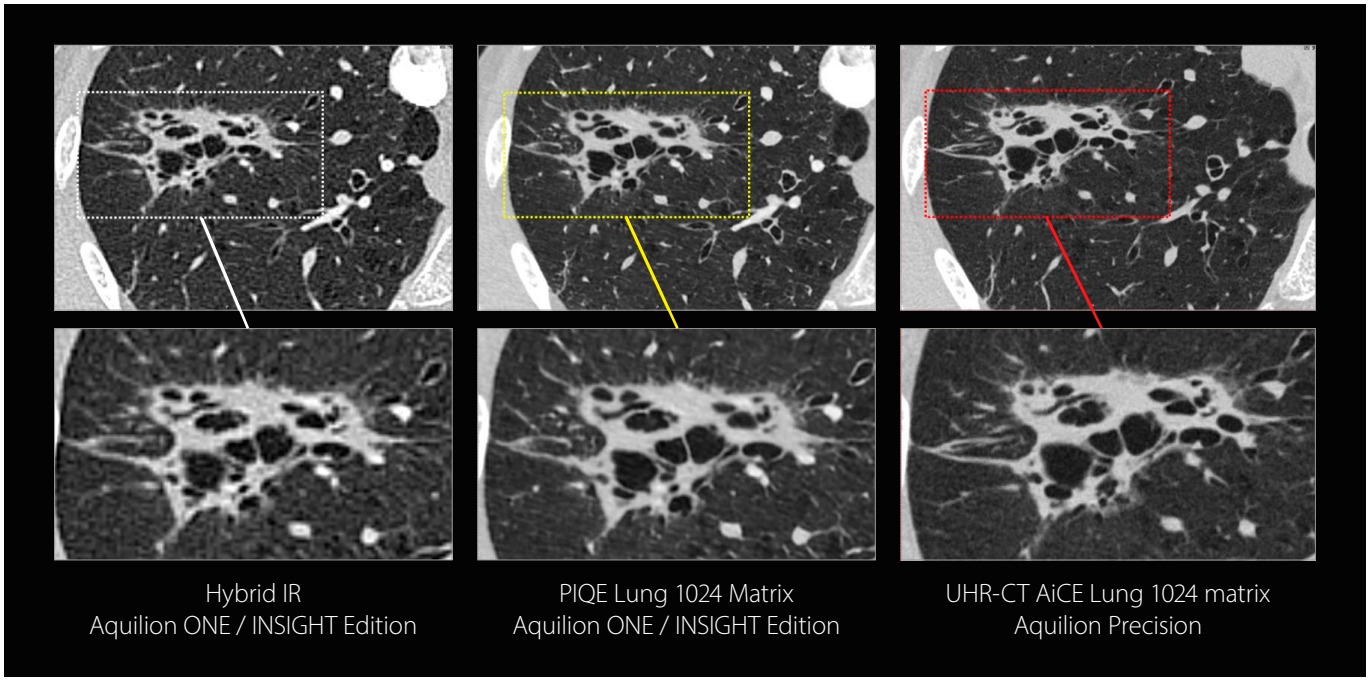

Figure 3: Comparison of a chest scan performed on Precision and a follow up scan performed with PIQE Lung 1024. Courtesy Ohara General Hospital, Japan

The neural network powering PIQE learns signal features in three dimensions, rather than being limited to the axial plane. As a result, image features are identified and preserved across all planes. This three-dimensional learning approach makes PIQE particularly well-suited for lung examinations, which are routinely assessed using multiplanar reconstructions (MPR) (Figure 4).

The authors participated in the initial evaluation of PIQE Lung 1024 in close collaboration with Canon engineers. As part of this effort, they have compiled a selection of clinical cases that demonstrate the diagnostic benefits of PIQE 1024 in lung CT.

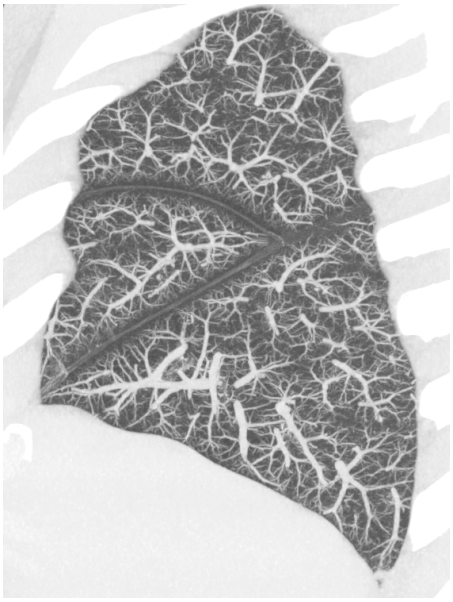

Figure 4: Sagittal view of the lungs demonstrating excellent image quality in MPR planes. Courtesy Prof Ohana, Strasbourg University Hospital, France

Testimonials



"PIQE Lung 1024 allows us to squeeze every last drop of spatial resolution out of our system. Lung detail is truly amazing and is making us re-evaluate our fundamental understanding of lung disease."

Dr. Russell Bull
Bournemouth Hospital, UK

"The high-resolution and low-noise images provided by the PIQE are useful for the qualitative and quantitative evaluation of various respiratory diseases."



Dr. Tae Iwasawa
Kanagawa Cardiovascular and Respiratory Center, Japan



"PIQE Lung 1024 Matrix sets a whole new level of quality and precision for the CT analysis of lung parenchyma. The level of detail is remarkable, at a level never seen before. It holds the potential to redefine the CT semiology of various lung conditions, such as interstitial lung diseases, infections, nodules, etc… Comparison with standard AiCE reconstruction is extremely helpful in understanding where and how PIQE can offer a clearer understanding of disease patterns."

Prof. Mickaël Ohana MD, PhD
Nouvel Hôpital Civil, Strasbourg University Hospital, France

"Super-Resolution Deep Learning Reconstruction (SR-DLR) with a 1024 matrix has revolutionized our chest imaging. The clinical image quality is unparalleled, and the thin slices generated by SR-DLR are exceptional for detailed lung parenchyma assessment."



Prof. Patrik Rogalla BS, MD, PhD, MBA
University Health Network, Toronto, Canada

Pulmonary Adenocarcinoma: Post-Radiation and Infectious Sequelae

Courtesy: Prof. Ohana, Strasbourg University Hospital, France

Patient History

A 69-year-old patient with a history of pulmonary adenocarcinoma treated by right upper lobectomy, chemotherapy, and radiotherapy (seven months ago) presented for reassessment following corticosteroid therapy for suspected post-radiation pneumonitis. Two weeks prior, the patient experienced respiratory distress with diffuse ground-glass opacities diagnosed as pneumocystosis.

Results

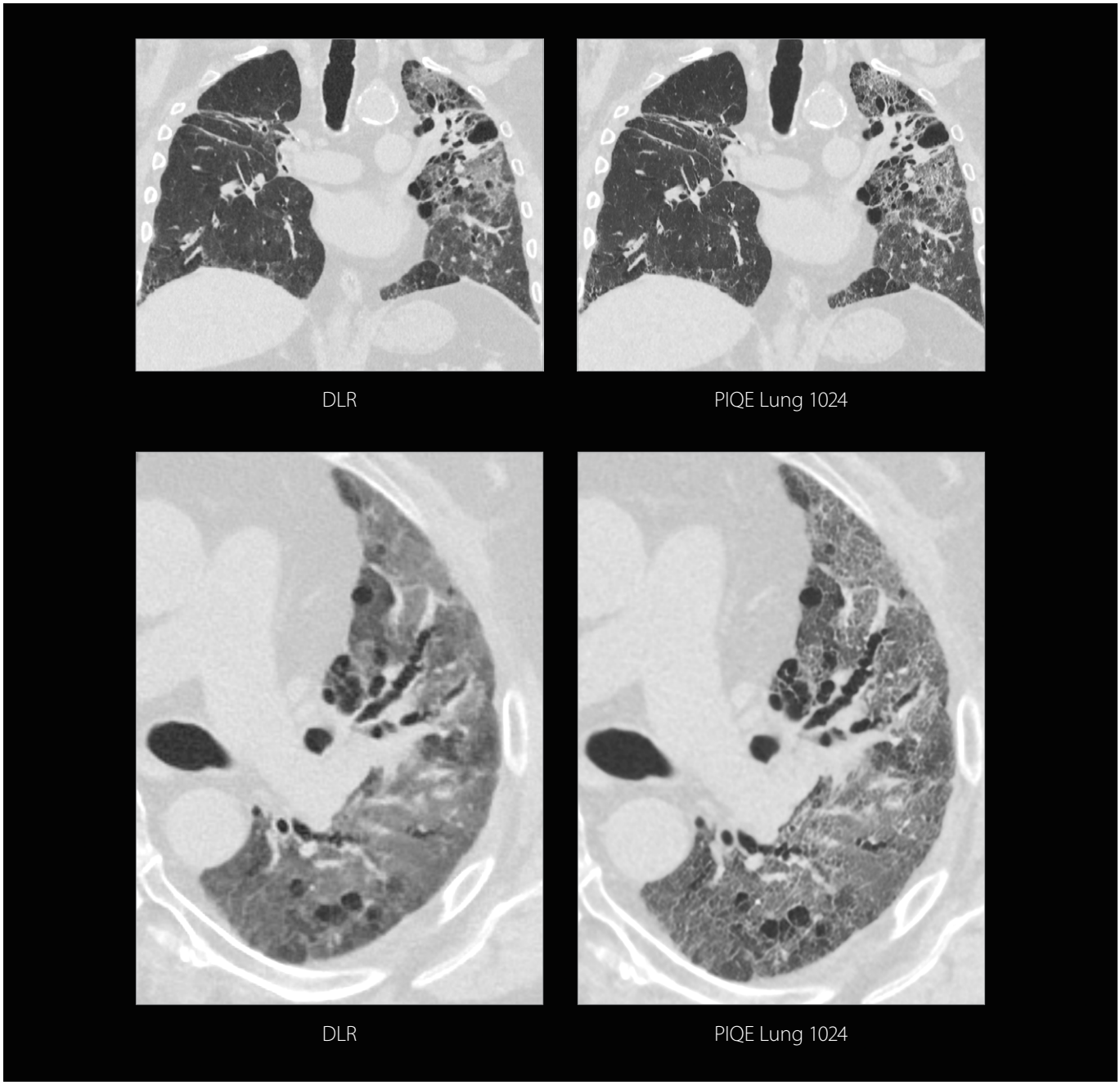

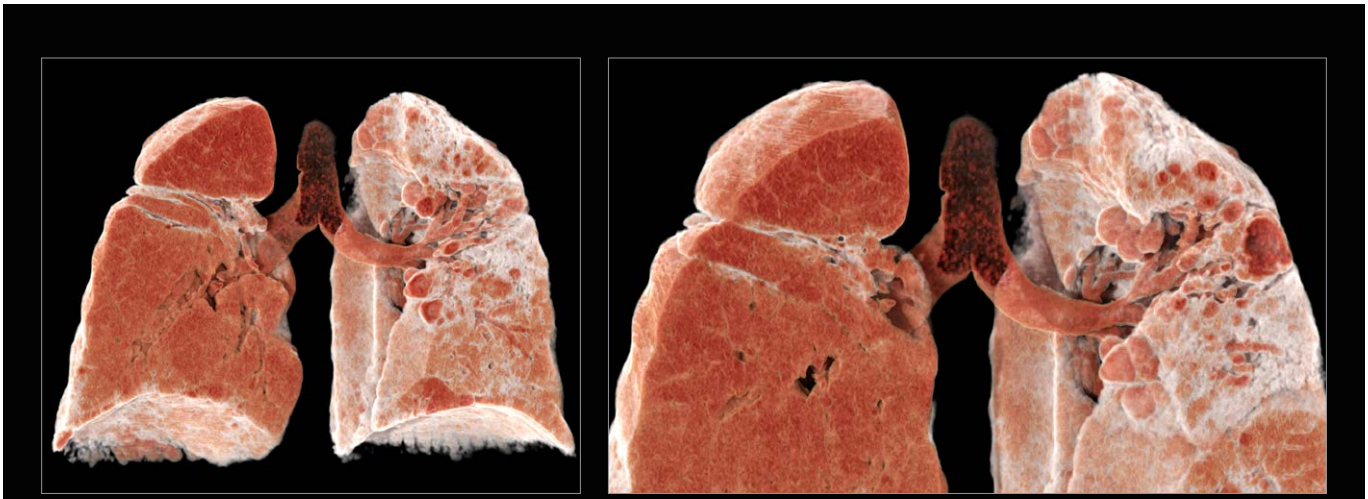

Global Illumination Rendering with PIQE Lung 1024

PIQE Lung 1024 provided a more detailed assessment of evolving pulmonary changes, particularly in the resolution of diffuse ground-glass opacities (GGO) compared to DLR. The high-resolution images revealed significant regression of GGOs, predominantly in the left lower and upper lobes, with clearly lower density compared to prior scans. Additionally, emerging bronchiectasis within the regressed GGOs was distinctly visualized, supporting the hypothesis of early fibrotic evolution.

Clinical Benefit

PIQE Lung 1024 provides exceptional spatial resolution, enabling precise differentiation of post-radiation sequelae, infectious changes, and early fibrotic evolution. Its ability to enhance fine reticulations, bronchiectasis changes, and subtle ground-glass variations allows for more confident disease assessment and long-term monitoring, ensuring early detection of fibrosis and treatment response evaluation.

Acquisition

Scan Parameters:	120 kV; SilverBeam filter
CTDI vol:	2 mGy
DLP:	74 mGy·cm
Effective Dose:	1 mSv (k=0.014)

Ground-Glass Opacity (GGO) Reassessment

Courtesy: Prof. Ohana, Strasbourg University Hospital, France

Patient History

A 62-year-old lung transplant recipient (2016) was referred for pulmonary parenchyma reassessment following pneumocystosis pneumonia treated with cotrimoxazole three months earlier.

Results

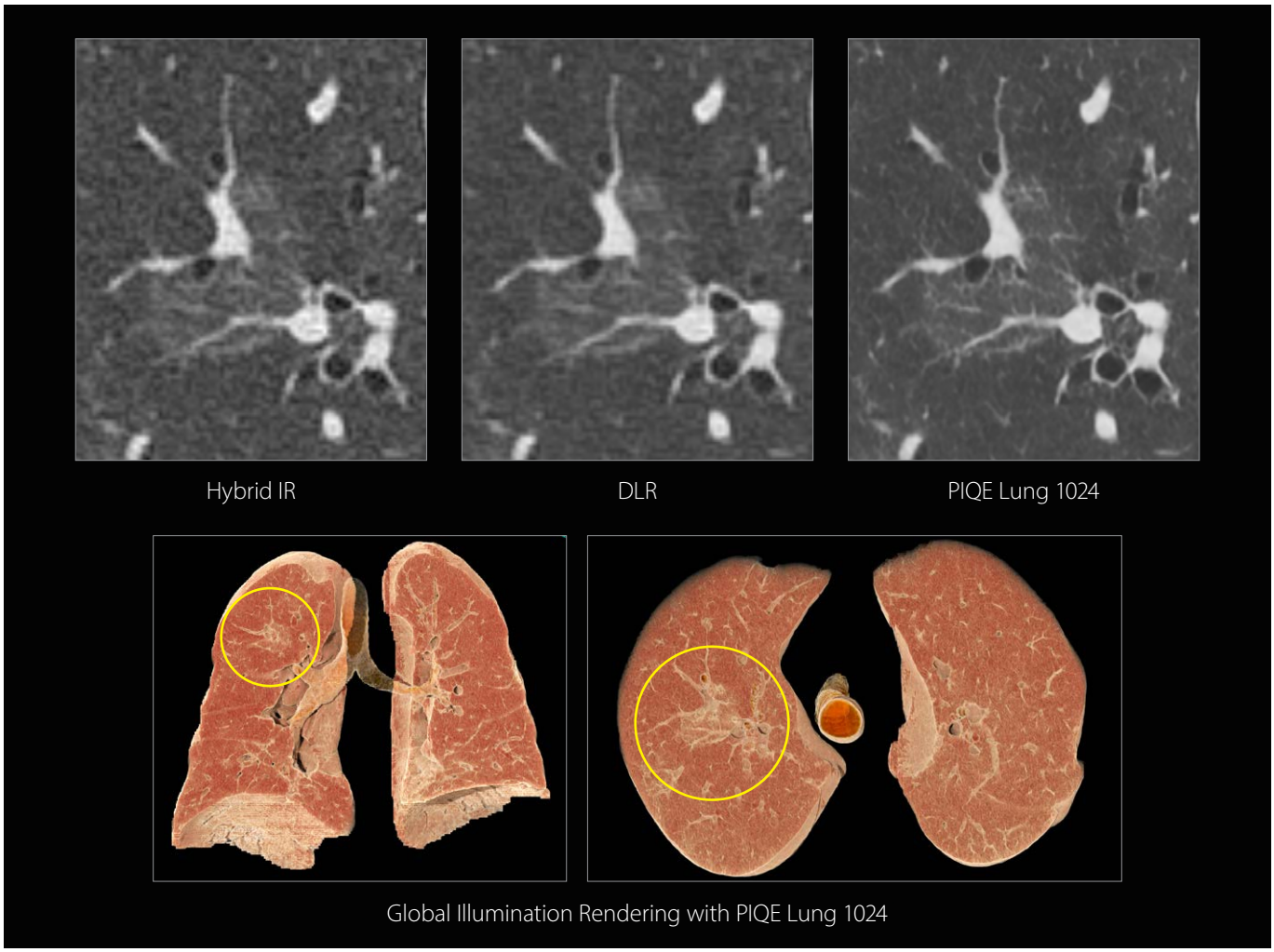

PIQE Lung 1024 matrix provided superior visualization of ground-glass opacities (GGO), allowing for a more precise evaluation of post-infectious changes. Compared to Hybrid-IR and DLR images, PIQE 1024 enabled clearer differentiation between regressive and persistent GGOs, revealing a transition from pseudo nodular condensations to low-density ground-glass regions. The improved spatial and low contrast resolution also highlighted subtle variations in GGO density and distribution, aiding in the assessment of disease evolution and potential early fibrosis.

Clinical Benefit

PIQE Lung 1024 enhances the detection and characterization of ground-glass opacities, crucial for monitoring post-infectious and post-transplant lung changes. Its High-Resolution capabilities improve disease assessment, aiding in early identification of progressive fibrosis or residual inflammation. This level of detail supports more precise patient management and treatment adjustments.

Acquisition

Scan Parameters:	120 kV; SilverBeam Filter
CTDI vol:	1.5 mGy
DLP:	53 mGy·cm
Effective Dose:	0.74 mSv (k=0.014)

Smoking Related Disease

Courtesy: Dr. Bull, Bournemouth Hospital, UK

Patient History

A high-resolution CT scan with SilverBeam Filter was ordered for an 84-year-old male with a known history of long-term smoking and dyspnea.

Results

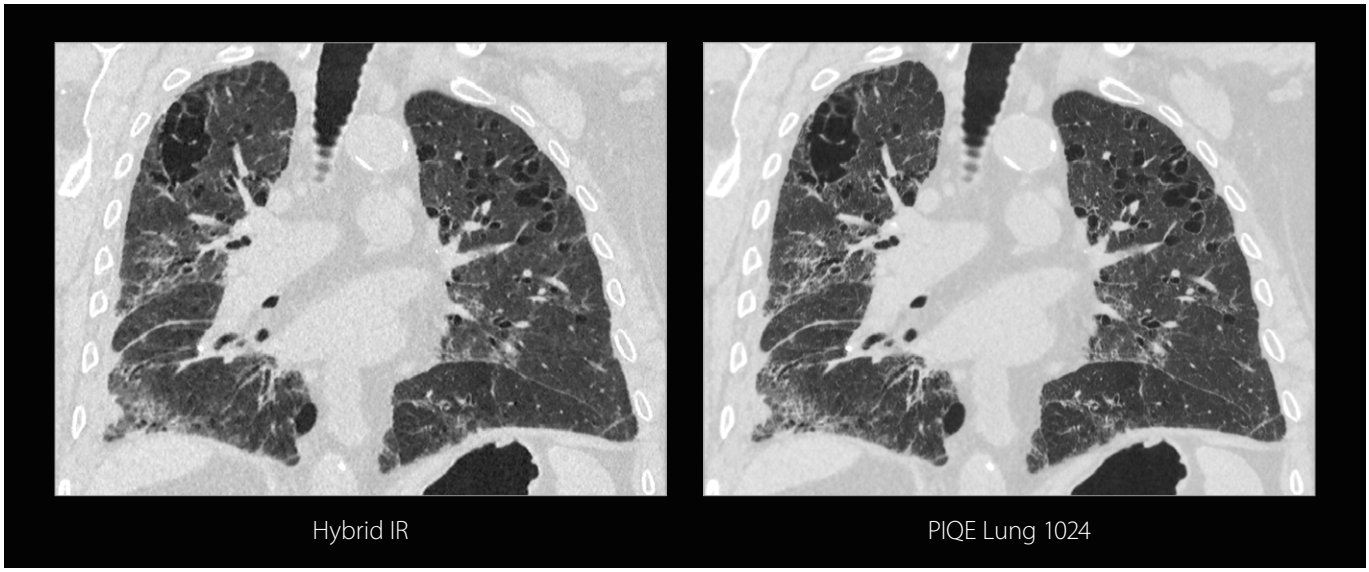

Hybrid IR PIQE Lung 1024

This study shows all the common features of smoking related lung disease, generalized bronchial wall thickening, multiple irregular upper lobe cysts consistent with Langerhans cell histiocytosis, extensive patchy reticular changes and traction bronchiectasis consistent with established extensive fine fibrosis.

Clinical Benefit

All the features are seen better on PIQE Lung 1024, compared to Hybrid IR, but the extensive fine fibrosis is only confidently diagnosed with the PIQE Lung 1024 image.

Acquisition

Scan Parameters:	120 kV
CTDI vol:	4.7 mGy
DLP:	316.5 mGy·cm
Effective Dose:	2.35 mSv (k = 0.014)

Hypersensitive Pneumonitis

Courtesy: Dr. Iwasawa, Kanagawa Cardiovascular and Respiratory Center, Japan

Patient History

A 79-year-old female patient presented with fibrotic hypersensitivity pneumonitis.

Results

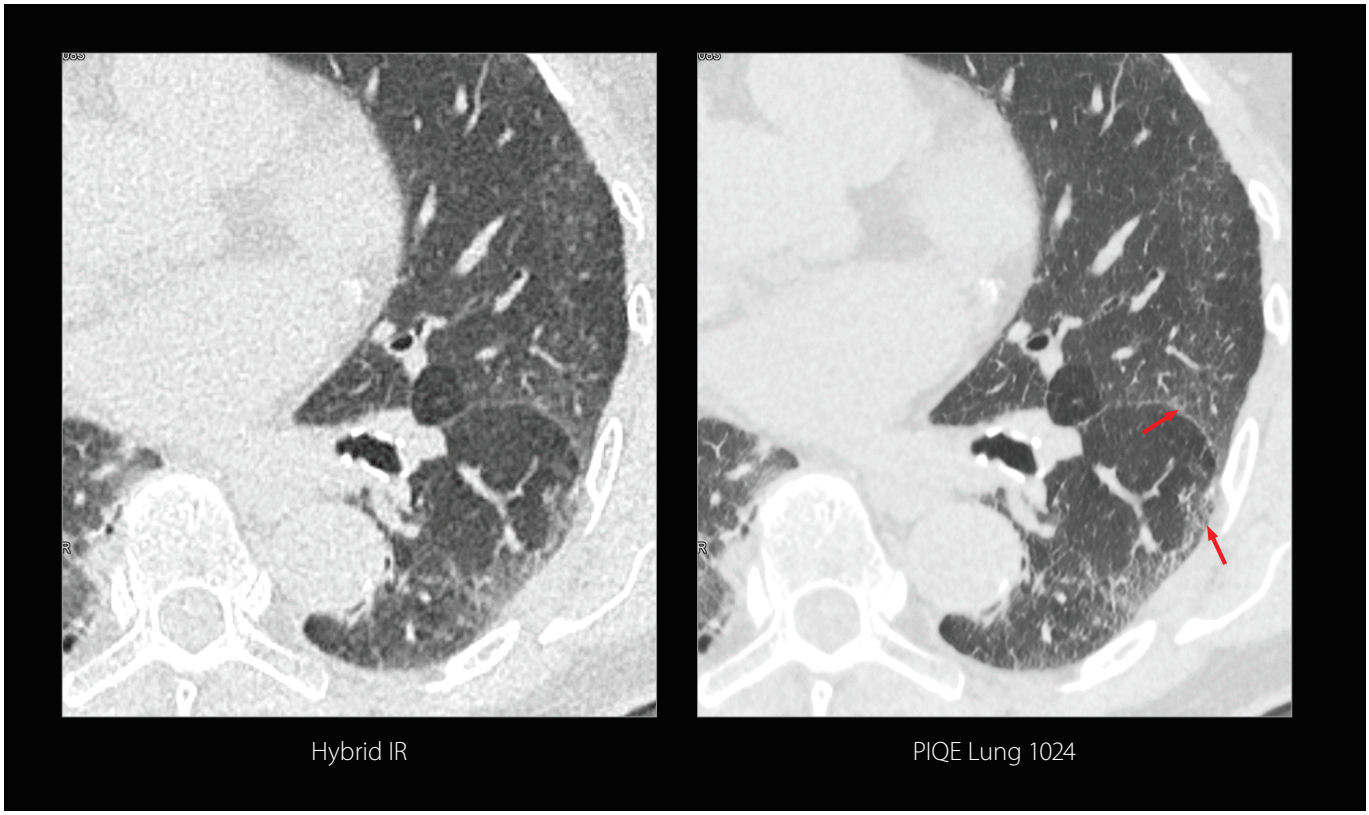

These are low-dose expiratory images obtained at optimal dose scan. Air trapping and patchy ground-glass opacities are visible in both images. The PIQE Lung 1024 images indicated that certain ground-glass opacities were composed of intralobular interstitial thickening and small nodules. Traction bronchiectasis was observed on PIQE Lung 1024 (red arrows).

Clinical Benefit

PIQE Lung 1024 demonstrates the composition of subtle ground glass opacities, even in an efficiently dose scan.

Acquisition

Scan Parameters:	120 kV
CTDI vol:	1.9 mGy
DLP:	52 mGy·cm
Effective Dose:	0.7 mSv (k=0.014)

Mosaic Lung Perfusion

Courtesy: Prof. Ohana, Strasbourg University Hospital, France

Patient History

An 88-year-old obese woman was referred for an Aorta CTA scan. A non-gated turbo helical (160 row collimation with 8 cm coverage at a rapid 0.24 second rotation speed) scan of the chest, abdomen, and pelvis was performed in the arterial phase, with a total scan time of 2.7 seconds.

Results

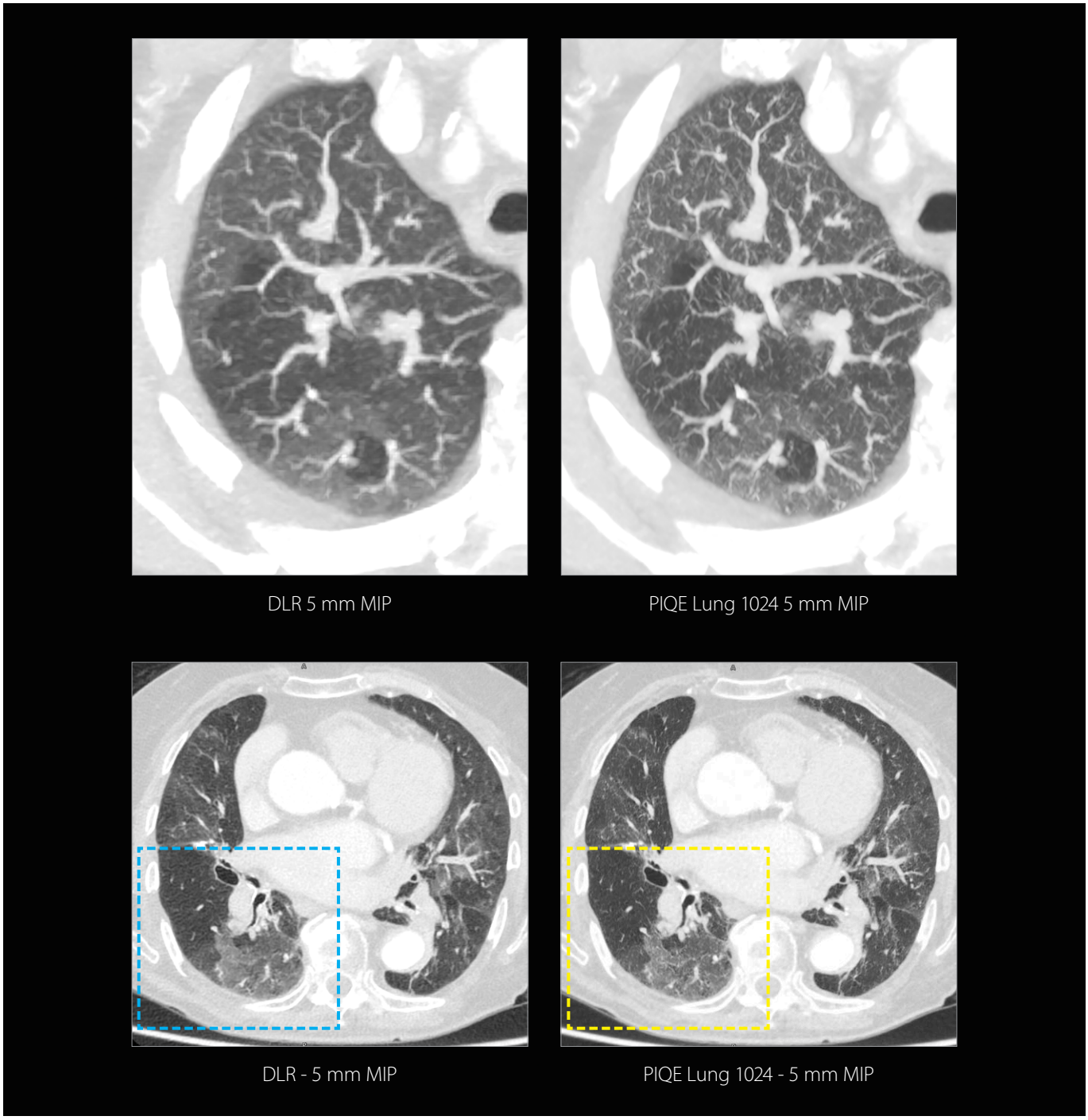

DLR 5 mm MIP

PIQE Lung 1024 5 mm MIP

DLR - 5 mm MIP

PIQE Lung 1024 - 5 mm MIP

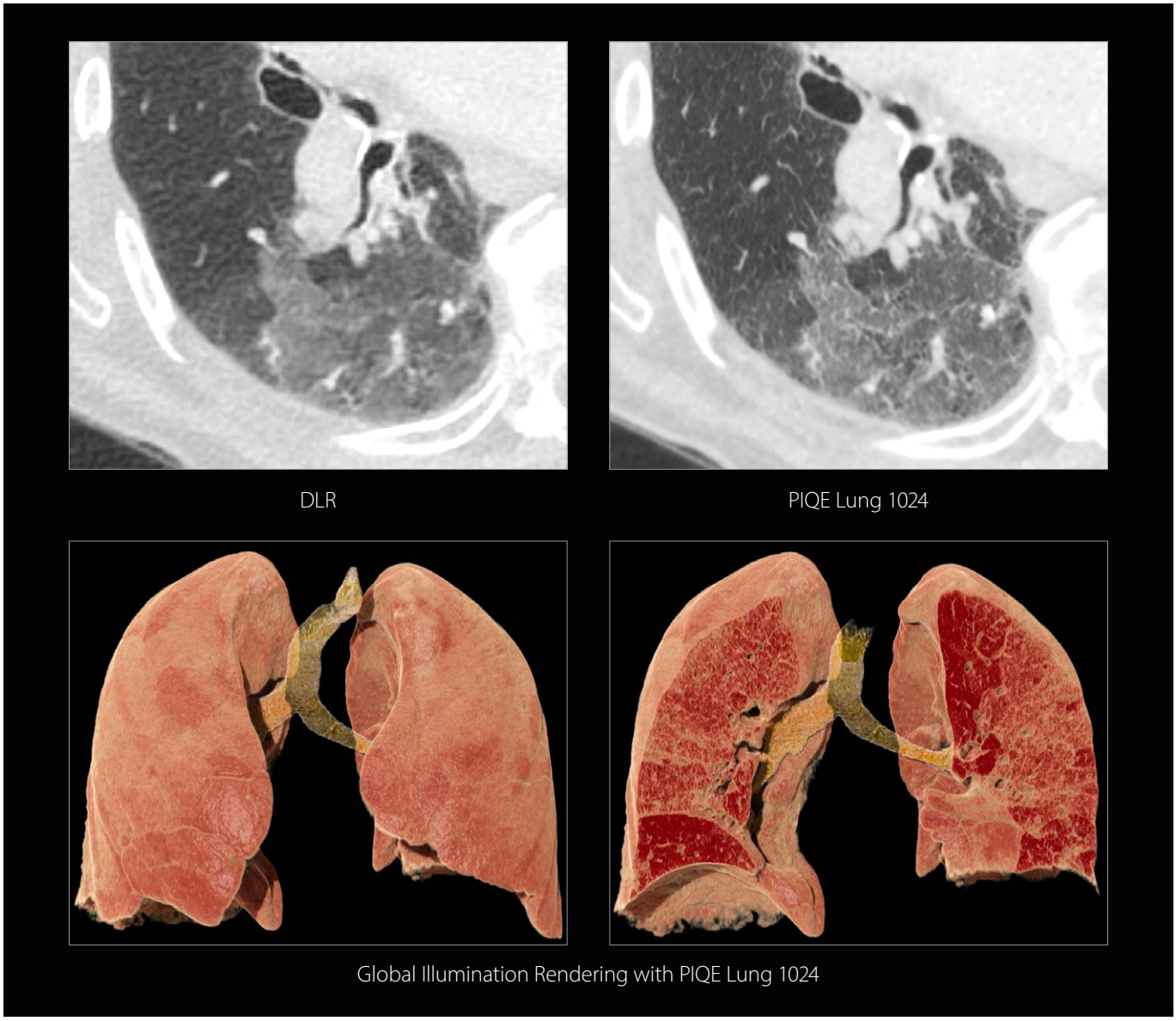

PIQE Lung 1024 Matrix provides an improved overall and detailed assessment of the mosaic attenuation pattern, in this case related to small airway disease. What was initially seen as pure ground glass opacities on the DLR images is better analyzed and depicted as fine small intra-lobular reticulations with PIQE 1024. Additionally, PIQE Lung 1024 provides enhanced visualization of smaller peripheral vessels and microcirculation in both hypo attenuated and hyper attenuated lung regions, providing a more precise evaluation of pulmonary perfusion.

Clinical Benefit

PIQE Lung 1024 offers a more detailed analysis of lung parenchymal structures, compared to conventional reconstruction algorithms, by providing a precise delineation of fine fibrotic abnormalities, enhancing the potential to refine the classification of ILD patterns. Additionally, sharp details are preserved while zooming, thanks to PIQE Lung 1024 Matrix.

Acquisition

Scan Parameters:	100 kV, Non-Gated Turbo Helical mode
CTDI vol:	3.4 mGy
DLP:	235 mGy·cm
Effective Dose:	3.3 mSv (k=0.014)

Pulmonary Neoplasia Re-evaluation

Courtesy: Prof. Ohana, Strasbourg University Hospital, France

Patient History

A 77-year-old patient underwent a venous phase Chest-Abdomen-Pelvis scan for reevaluation of pulmonary neoplasia.

Results

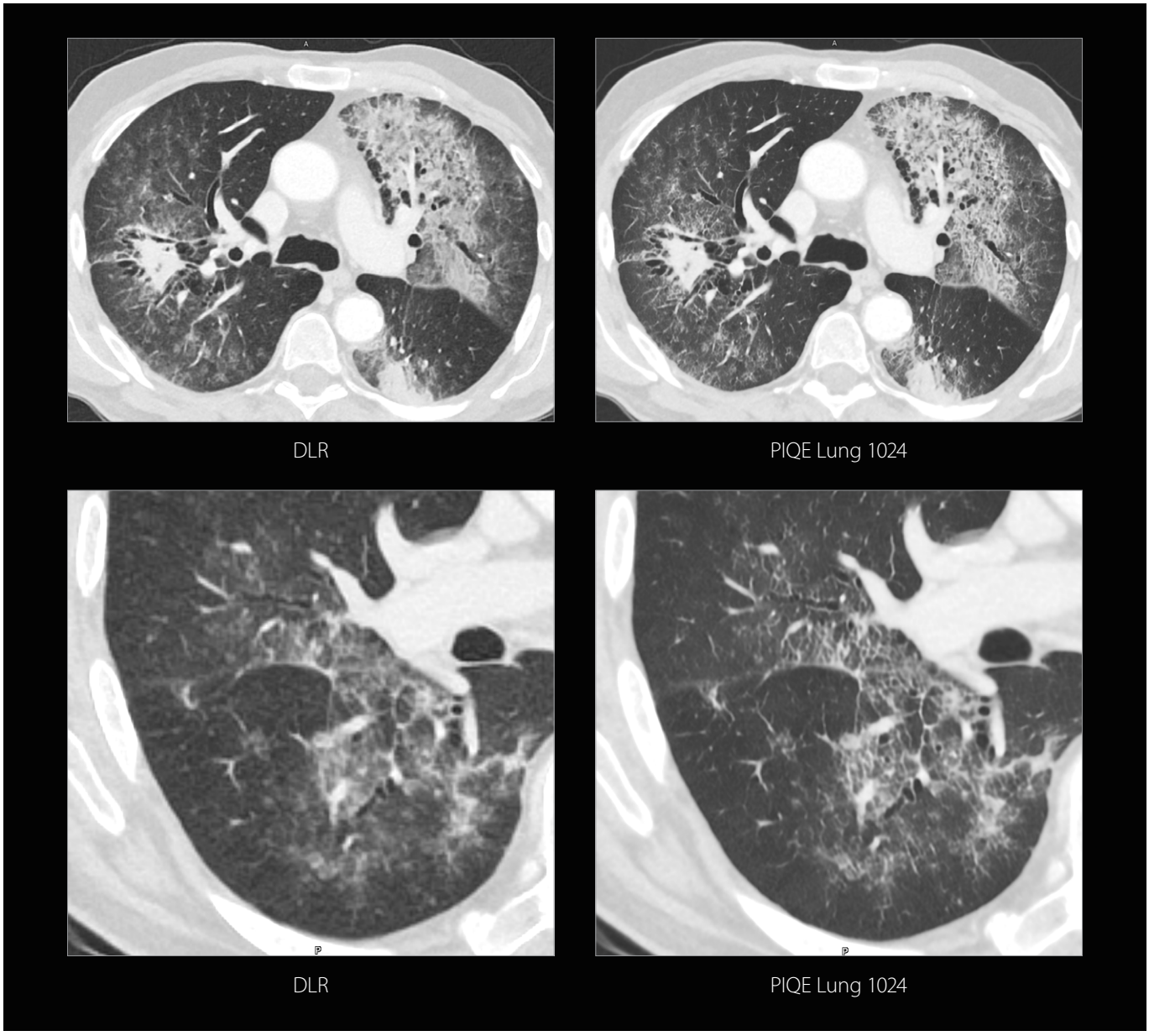

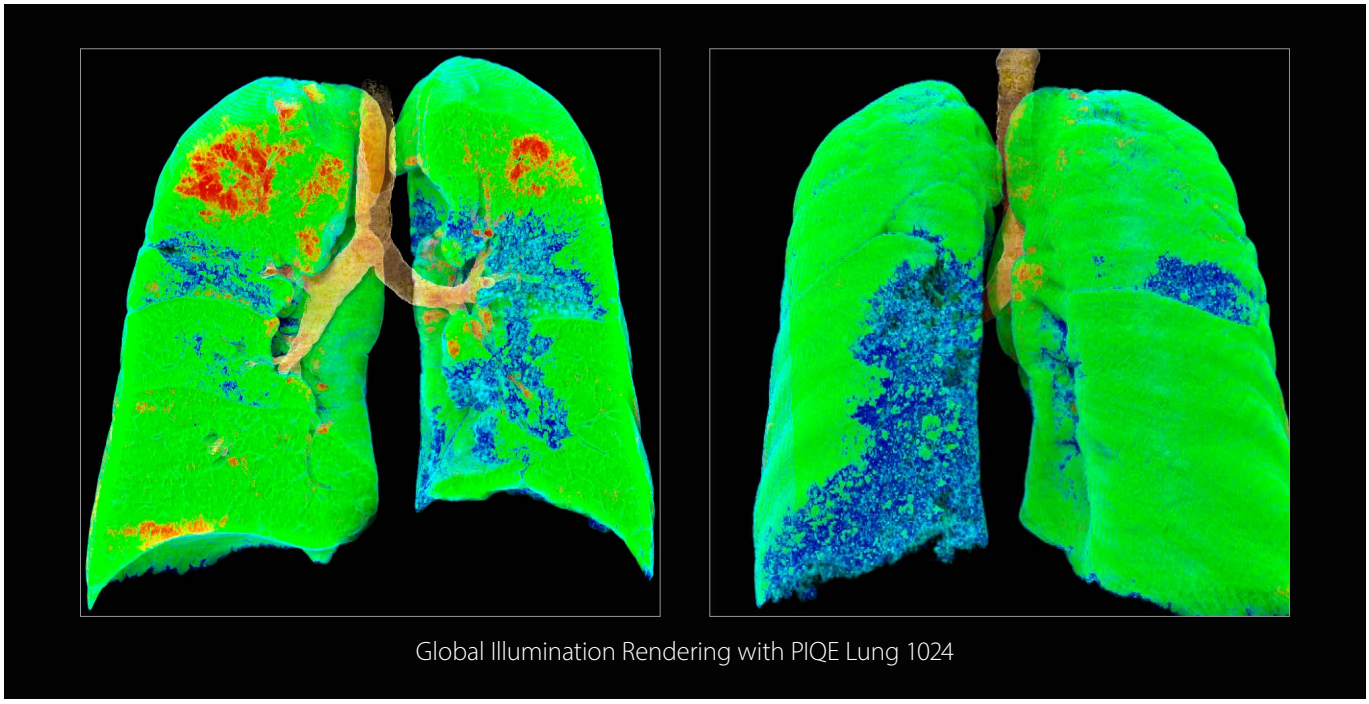

Global Illumination Rendering with PIQE Lung 1024

PIQE Lung 1024 provided enhanced visualization of the lung parenchyma, compared to DLR, allowing for a more precise assessment of alveolar consolidation and ground-glass opacities. Pseudonodular ground-glass opacities with internal reticulations were more clearly delineated, particularly in the posterior part of the lesion and specific segments of the right and left lobes.

Clinical Benefit

PIQE Lung 1024 offers improved visualization of small airway structures, emphysema, and interstitial lung disease features compared to DLR. In this case, the improved visualization of reticulations and ground-glass abnormalities allows for more precise disease monitoring and classification, particularly in oncologic follow-up cases.

Acquisition

Scan Parameters:	100 kV
CTDI vol:	3.2 mGy
DLP:	219 mGy·cm
Effective Dose:	3 mSv (k=0.014)

Lung Cancer

Courtesy: Dr. Iwasawa, Kanagawa Cardiovascular and Respiratory Center, Japan

Patient History

A 70-year-old female patient presented with a nodule in the upper left lobe. The patient was never a smoker, and her pulmonary function test results were normal. Emphysema was not observed in the lungs.

Results

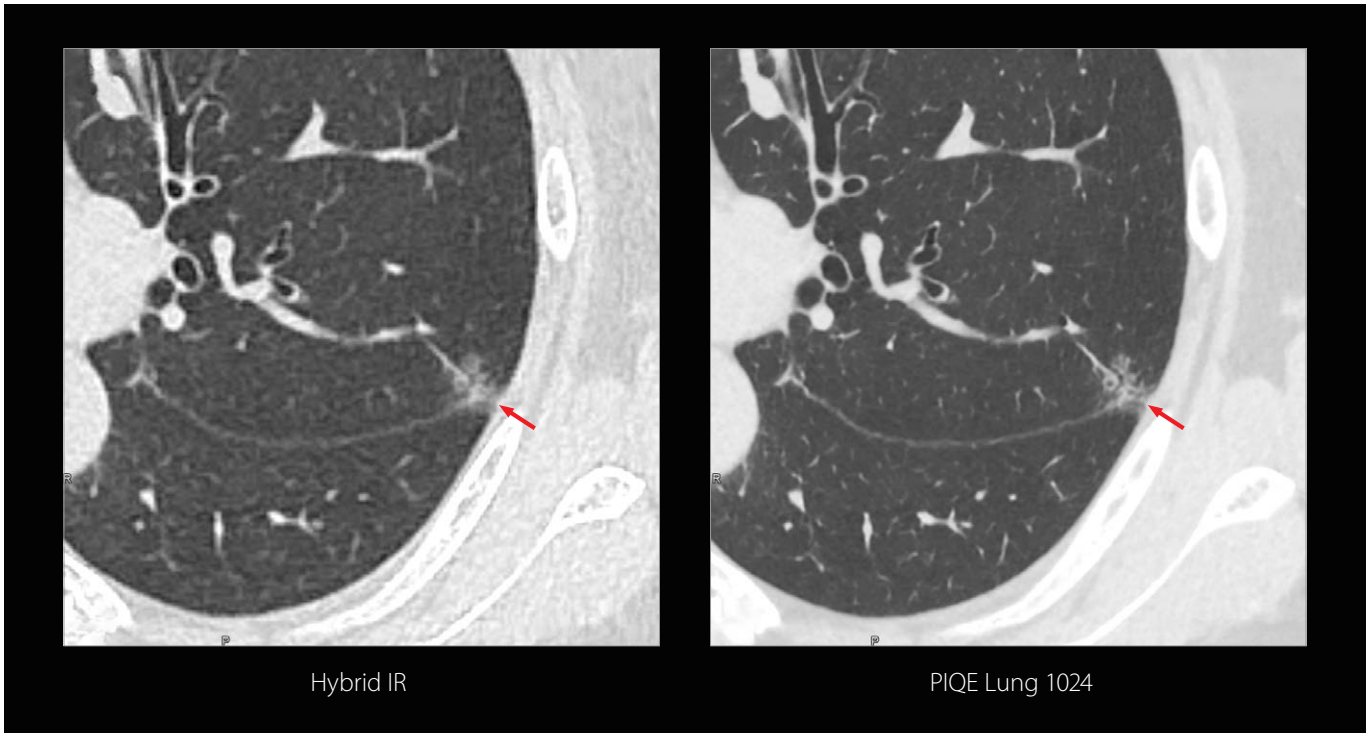

A ground-glass nodule (red arrows) in the left upper lobe is visible in both of images; Hybrid IR on the left and PIQE Lung 1024 on the right. Increased CT attenuation within the nodule and interlobular pleural indentation suggested the presence of lung cancer. However, irregular airspace dilatation within the nodule is visible in the PIQE Lung 1024 image. The surgical specimens confirmed the diagnosis of adenocarcinoma in situ.



PIQE Lung provides extraordinary spatial resolution with reduced noise, even when using a 1024 matrix. This low noise level is particularly significant for quantitative evaluation of emphysema[4]. In this patient, the %LAA was 14.6% with hybrid IR but only 0.5% with PIQE Lung 1024.

Additionally, the PIQE Lung images with a 1024 matrix demonstrated the peripheral bronchi, especially when compared with the hybrid IR images with a 512 matrix. This improvement is expected to enhance the accuracy of bronchoscopic navigation in patients with lung cancer[5].

Clinical Benefit

PIQE Lung 1024 reveals additional features, such as airspace dilatation and peripheral bronchiole disruption, which are critical for lung cancer assessment.

Acquisition

Scan Parameters:	120 kV
CTDI vol:	7.7 mGy
DLP:	346.3 mGy·cm
Effective Dose:	4.8 mSv (k=0.014)

Tumor

Courtesy: Prof. Patrik Rogalla, University Health Network, Toronto, Canada

Patient History

A chest and abdomen CT was requested for cancer staging.

Results

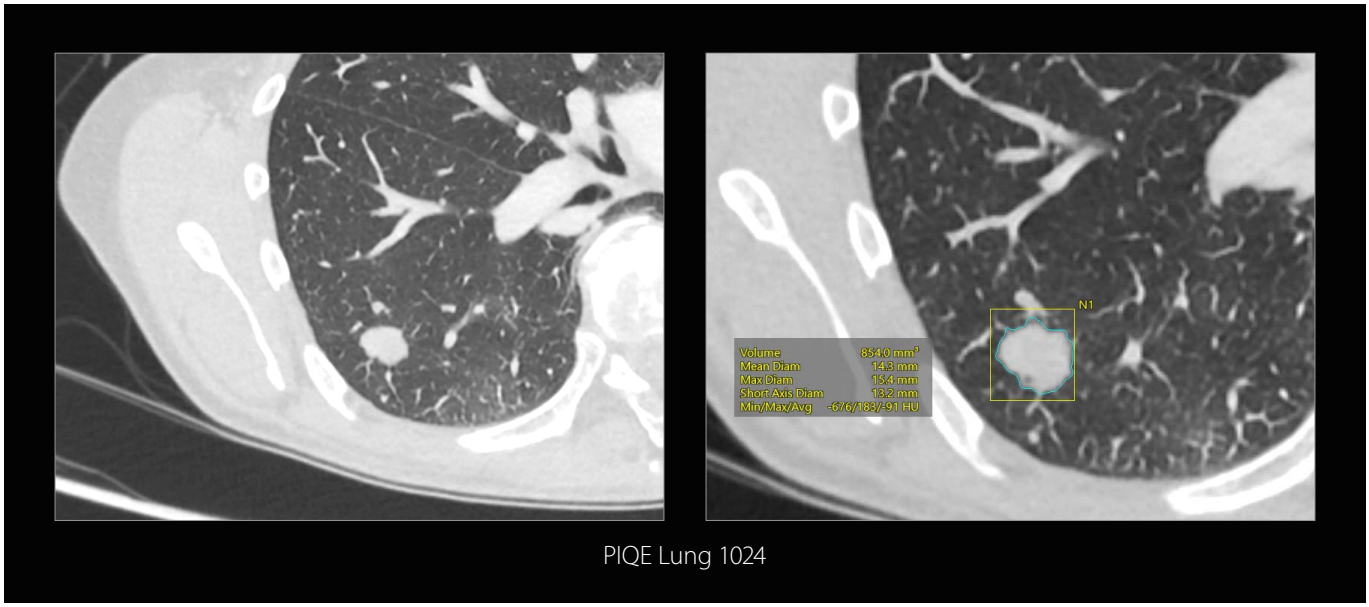

PIQE Lung 1024

A 15 mm nodule is seen in the right lower lobe. The shape of the nodule and in particular its relationship with neighboring structures is better appreciated with PIQE reconstruction.

Clinical Benefit

The improved spatial resolution in PIQE Lung 1024, leading to a better delineation of lung structures, helps with characterizing the nodule and planning of a lung biopsy.

Acquisition

Scan Parameters:	120 kV
CTDI vol:	3.7 mGy
DLP:	253 mGy·cm
Effective Dose:	3.67 mSv (k= 0.0145)

Comprehensive Lung Nodule Assessment in Stage 2 COPD

Courtesy: Prof. Ohana, Strasbourg University Hospital, France

Patient History

A 71-year-old patient with Stage 2 COPD underwent an annual follow-up CT scan for lung nodule surveillance.

Results

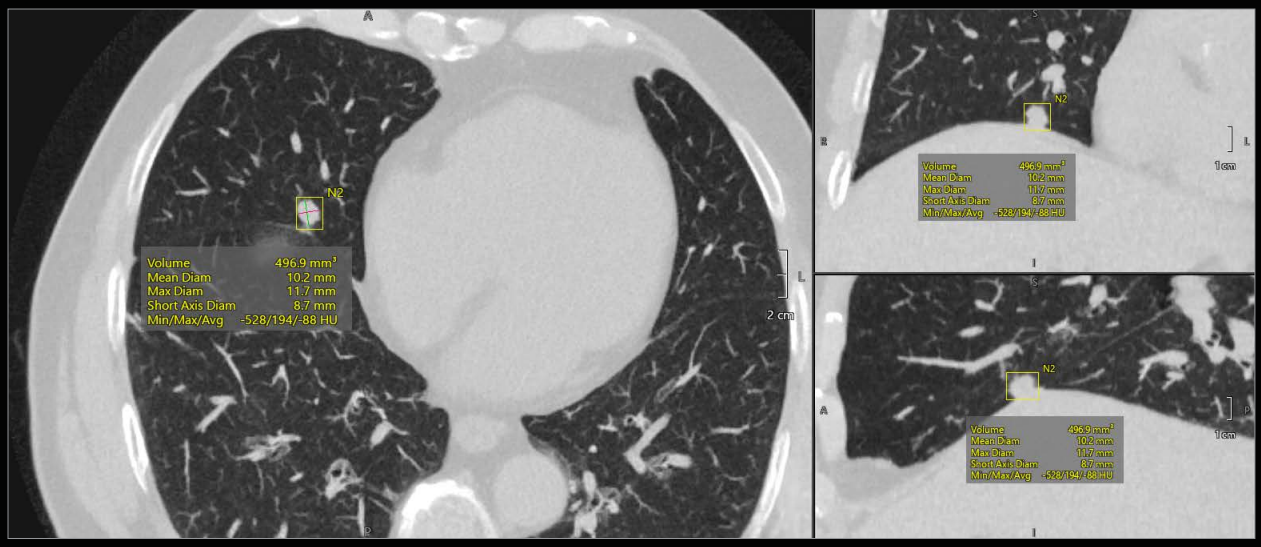

PIQE Lung 1024 with Vitrea Lung Nodules CAD

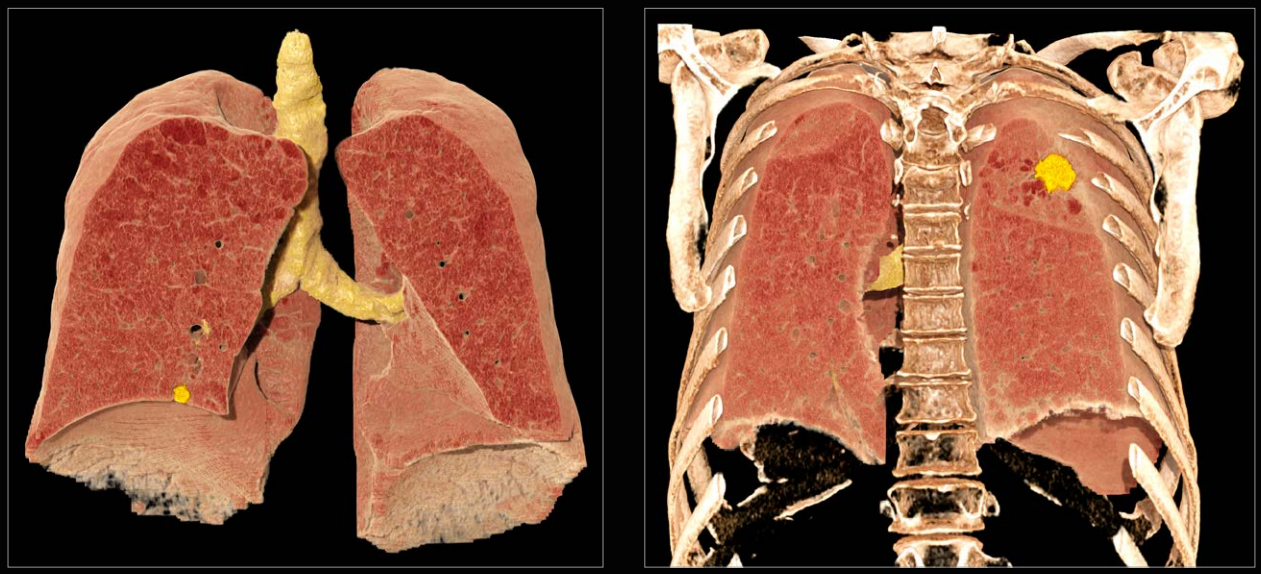

Global Illumination Rendering with PIQE Lung 1024

The scan demonstrated transformation of a pre-existing subpleural lesion in the posterior segment of the right upper lobe into a solid nodule (26 × 20 mm), suspicious for malignancy. A new 11 mm solid subpleural nodule in the middle lobe with spiculated contours, a feature concerning for potential malignancy, was also shown. High-resolution PIQE Lung 1024 provided precise nodule characterization and spiculation visibility, aiding malignancy risk assessment. Integration with advanced post-processing (Lung Nodule CAD) enhanced nodule detection and volumetric tracking.

Clinical Benefit

The combination of PIQE Lung 1024, SilverBeam Filter, and Lung Nodule CAD provides a powerful, comprehensive solution for lung nodule assessment. PIQE Lung 1024's high resolution enhances nodule characterization and spiculation visibility, while the SilverBeam Filter ensures dose efficiency for safe long-term follow-up. Lung Nodule CAD enables precise detection, volumetric tracking, and streamlined workflow, supporting earlier diagnosis and intervention for improved patient outcomes.

Acquisition

Scan Parameters:	120 kV; SilverBeam Filter
CTDI vol:	1.8 mGy
DLP:	63 mGy·cm
Effective Dose:	0.8 mSv (k= 0.014)

Lung Micro-Nodules

Courtesy: Prof. Ohana, Strasbourg University Hospital, France

Patient History

A 64-year-old former smoker with a history of chronic cough and mild dyspnea underwent a routine non-contrast chest CT for lung health assessment. No prior nodules had been reported in previous scans.

Results

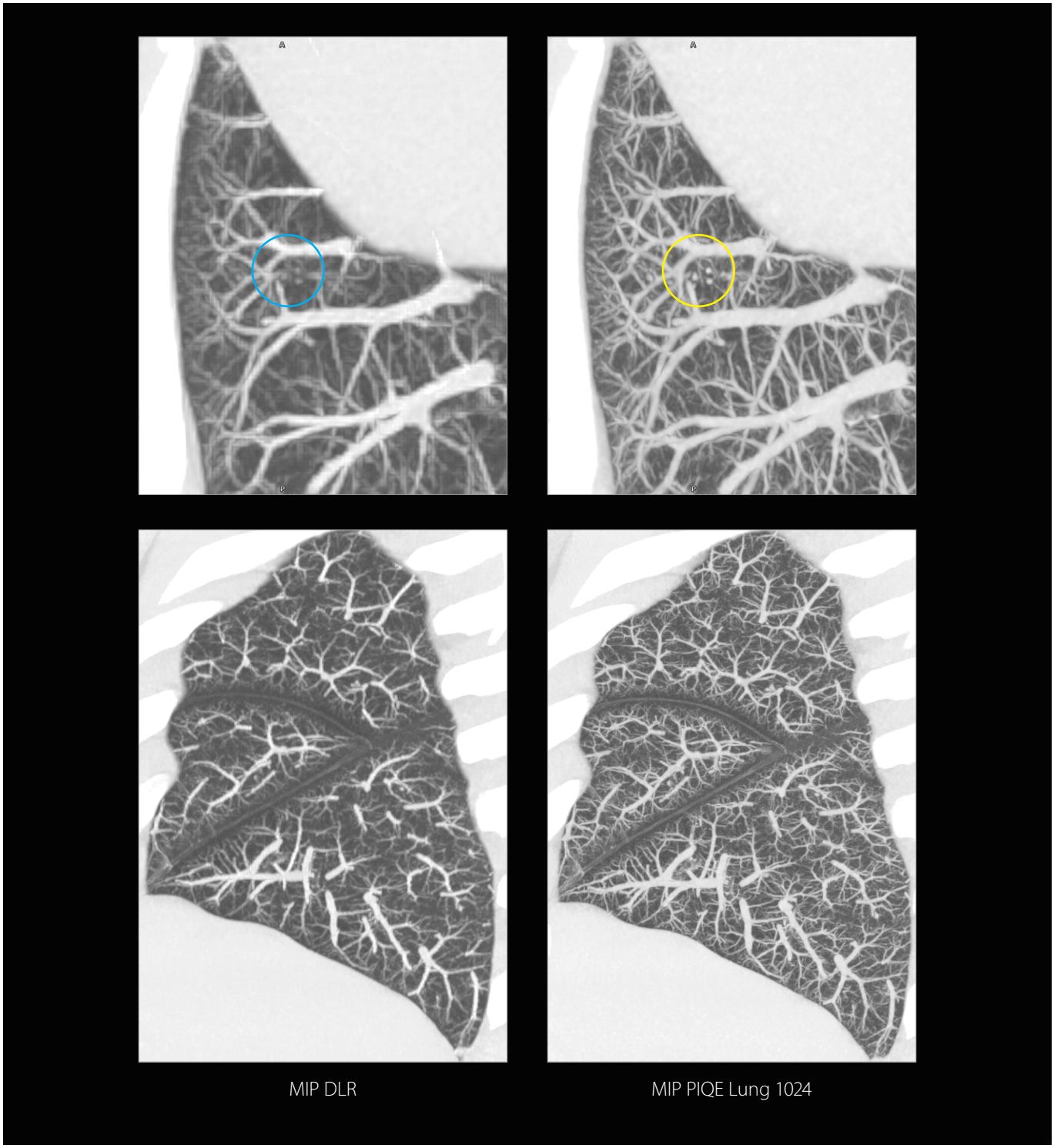

PIQE Lung 1024 enabled the detection of three previously unreported micro-nodules in the right lower lobe, which were not clearly visible on the DLR images. The improved spatial resolution also significantly enhanced the visualization of pulmonary vessels and the fissure, providing better anatomical clarity for evaluating lung structures.

Clinical Benefit

PIQE Lung 1024 provides superior spatial resolution, allowing for earlier and more confident detection of micro-nodules, which is critical for lung cancer screening and follow-up. Additionally, the enhanced delineation of pulmonary vessels and fissures supports more precise anatomical assessment, improving diagnostic confidence in lung imaging.

Acquisition

Scan Parameters:	100 kV
CTDI vol:	3.2 mGy
DLP:	96 mGy·cm
Effective Dose:	1.3 mSv (k= 0.014)

Pulmonary Arteries Stent Evaluation

Courtesy: Prof. Ohana, Strasbourg University Hospital, France

Patient History

An obese patient with a history of bilateral pulmonary artery stenosis underwent stent placement in the right and left pulmonary arteries. One year ago, the patient developed dyspnea, but cardiac reassessment showed no pulmonary arterial hypertension. A CT Pulmonary Angiography (CTPA) was performed for routine stent surveillance and pulmonary vascularization assessment after angioplasty.

Results

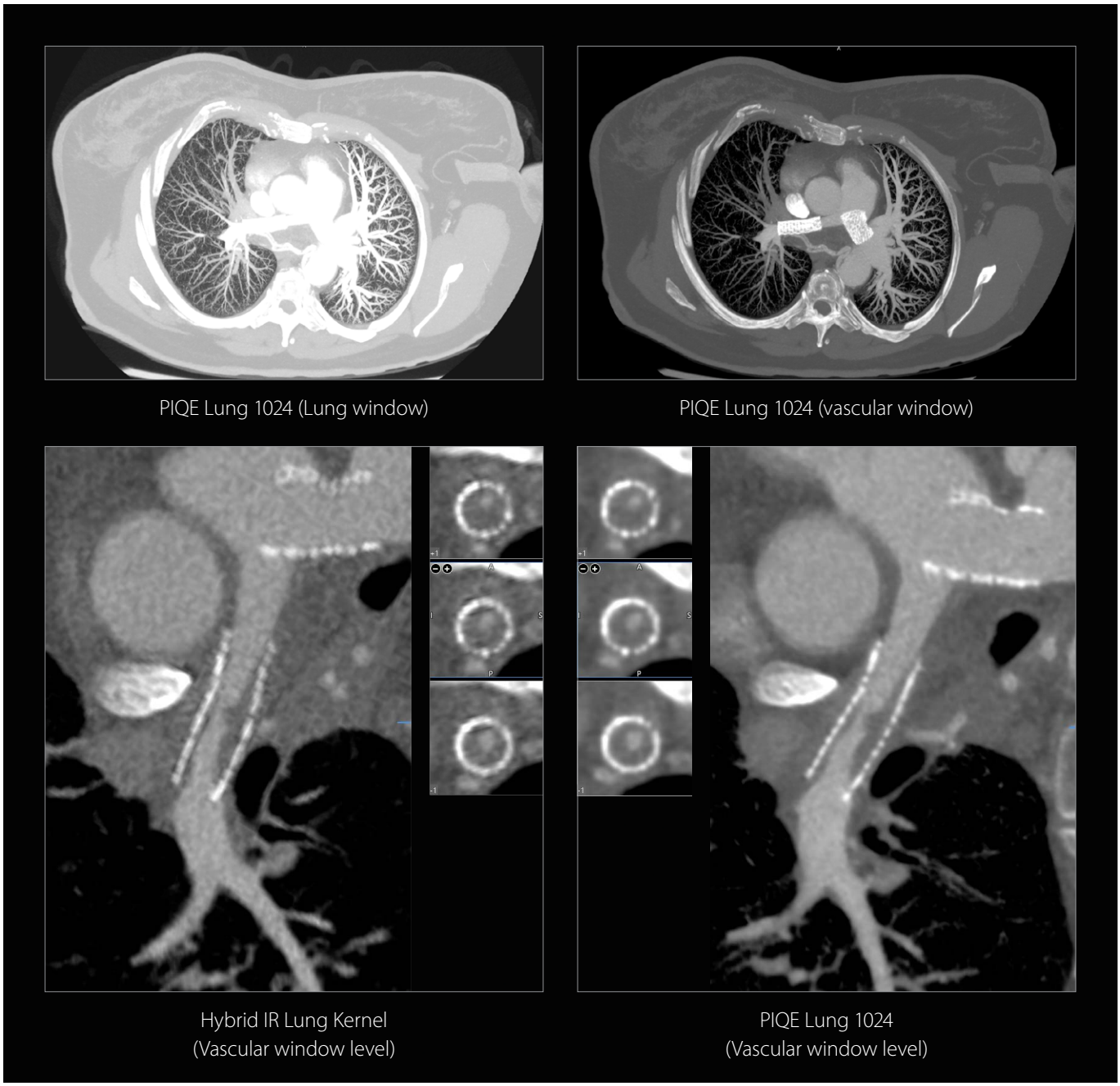

PIQE Lung 1024 (Lung window)

PIQE Lung 1024 (vascular window)

Hybrid IR Lung Kernel
(Vascular window level)

PIQE Lung 1024
(Vascular window level)

Compared to previous scans, there was a relative increase in the near-circumferential in-stent thrombus within the right pulmonary artery, becoming pre-occlusive in its middle third. The left pulmonary artery stent remained patent. Findings were consistent with chronic thromboembolic disease, including significant reduction in right pulmonary arterial perfusion, hypertrophy of the bronchial arteries, and parenchymal consequences.

Traditionally, soft tissue kernels are preferred for vessel assessment. However, PIQE Lung 1024's low-noise properties and high resolution provided excellent pulmonary artery visualization, allowing detailed evaluation of the in-stent thrombosis in the right pulmonary artery.

Clinical Benefit

In this case, PIQE Lung 1024's advanced image quality enabled simultaneous high-resolution evaluation of lung and vascular structures, improving diagnostic accuracy, workflow and reading efficiency for clinicians. By reducing the need for multiple reconstructions, it streamlines clinical decision-making and enhances stent surveillance in complex pulmonary vascular diseases.

Acquisition

Scan Parameters:	100 kV
CTDI vol:	6 mGy
DLP:	188 mGy·cm
Effective Dose:	2.6 mSv (k= 0.014)

Conclusion

PIQE brings excellent spatial resolution and reduced noise while maintaining low contrast detectability. PIQE may improve visualization of ground glass opacities and fibrosis, improved evaluation of low attenuation areas, excellent cyst definition and accurate nodule measurement. PIQE meets the guidelines for ILD imaging from various thoracic societies[1].

The cases in this white paper represent the full range of clinical value of PIQE 1024 for lung applications.

References

1. Hague C, McInnis M, Souza C. High Resolution CT of the Chest Recommended Technique. https://car.ca/wp-content/uploads/2020/02/High-Resolution-CT-of-the-Chest-Recommended-Technique-2020.pdf
2. HRCT of the Chest. European Respiratory Society; -01 00:00:00. doi: 10.1183/9781849840415.015112
3. Boedeker K. PIQE White Paper. Published online 2022.
4. Iwasawa T, Matsushita S, Hirayama M, Baba T, Ogura T. Quantitative Analysis for Lung Disease on Thin-Section CT. Diagnostics (Basel) 2023;13(18). doi: 10.3390/diagnostics13182988
5. Morita Y, Yamashiro T, Tsuchiya N, Tsubakimoto M, Murayama S. Automatic bronchial segmentation on ultra-HRCT scans: advantage of the 1024-matrix size with 0.25-mm slice thickness reconstruction. *Jpn J Radiol* 2020;38(10):953-959. doi: 10.1007/s11604-020-01000-9

Altivity

Altivity is a new approach to AI innovation. It is a multimodality, overarching brand for healthcare, which pulls together all the AI technology that Canon provides under one name.

Canon

CANON INC.

30-2, Shimomaruko 3-chome, Ohta-ku, Tokyo 146-8501, Japan
Telephone: (81)-3-3758-2111
©CANON INC. 2025-2026. All rights reserved.
Design and specifications are subject to change without notice.
Model number: TSX-304A
MWPCT0016EAB 2026-04 Published in Japan

The clinical results described in this paper are the experience of the authors.
Results may vary due to clinical setting, patient presentation and other factors.

CANON MEDICAL GROUP

Made For life