CT / White paper

Cardiac CT with Precise IQ Engine (PIQE) 1024 Matrix in Clinical Practice



Dr. Marcus Chen
National Heart, Lung & Blood Institute
National Institutes of Health, USA



Prof. Mickaël Ohana
Nouvel Hopital Civil, Strasbourg University Hospital, France



Dr. Fuminari Tatsugami
Hiroshima University, Japan

Introduction

Cardiovascular disease is the leading cause of death worldwide[1]. Early diagnosis of cardiovascular disease is important for improved life expectancy and effective treatment planning. Cardiac CT Angiography (CCTA) is a non-invasive test to diagnose coronary artery disease (CAD). A multi-center international study has shown that cardiac CTA accurately identifies the presence and severity of obstructive coronary artery disease and subsequent revascularization in symptomatic patients[2].

Recently both the US and European guidelines for the diagnosis of patients with chest pain have been updated. In the European guidelines cardiac CTA is recommended to exclude acute coronary syndrome in patients with low to intermediate likelihood of CAD[3]. In the US guidelines cardiac CTA is recommended as a frontline test for the evaluation of patients with stable and acute chest pain who have no history of CAD[4]. In both guidelines cardiac CTA has a Class 1 Level A designation which is the strongest recommendation indicating high quality evidence from clinical trials that CTA is beneficial, useful and safe[3,4].

The Coronary Artery Disease Reporting and Data System (CAD-RADS) provides a standardized reporting framework for coronary CT angiography and was updated in 2022. The classification system provides an assessment of stenosis and plaque burden and a guide to possible next steps in patient management[5] (Figure 1).

Precise IQ Engine (PIQE) is a Super Resolution Deep Learning Reconstruction* that brings together extraordinary spatial resolution and reduced noise, within a single-rotation scan for confident diagnosis of small coronary vessels, plaques, stents and fine cardiac structures (Figure 2).

CAD-RADS categories

Score	Stenosis	Interpretation	Further investigation
0	0%	Absence of CAD	None
1	1–24%	Minimal non-obstructive CAD	None
2	25–49%	Mild non-obstructive CAD	None
3	50–69%	Moderate stenosis	Consider functional assessment
4A	70–99% single or 2- vessel	Severe stenosis	Consider ICA or functional assessment
4B	Left main >50% or 3- vessel ≥70%		ICA
5	100%	Total coronary occlusion	Consider ICA and viability assessment
CadRads N	Non-diagnostic study	Obstructive CAD cannot be excluded	Additional evaluation needed

Figure 1: CAD-RADS Scoring system for coronary CTA. From https://radiologyassistant.nl/cardiovascular/cad-rads/coronary-artery-disease-reporting-and-data-system

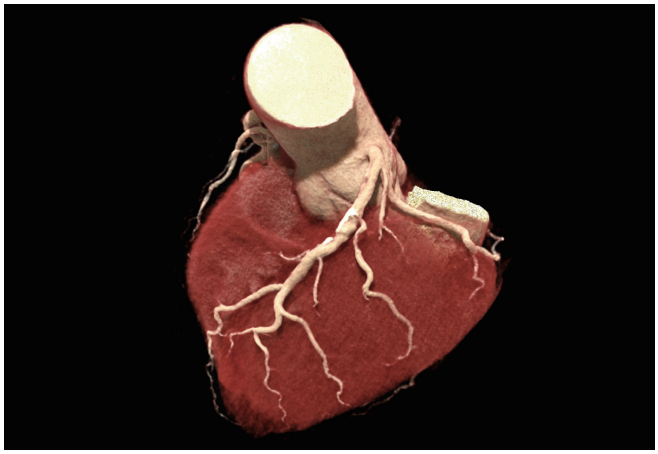

Figure 2: Single rotation cardiac CTA reconstructed with PIQE 1024

* In clinical practice, the use of PIQE may increase spatial resolution (super resolution), depending on the clinical task, patient size, anatomical location, and clinical practice.

The PIQE Deep Learning Reconstruction algorithm is trained using Ultra-High Resolution data with twice the resolution of conventional CT acquired on the commercially available Aquilion Precision CT system, which features UHR 0.25 mm detectors in routine clinical practice. Datasets reconstructed with PIQE empower the clinician with twice the high contrast signal definition, as well as reduced noise, in all three dimensions, relative to conventional hybrid iterative reconstruction. These benefits maintain low contrast detectability, without additional radiation dose to the patient[6] (Figure 3).

The extraordinary spatial resolution of PIQE images reconstructed with 1024 matrix is also beneficial in other cardiac applications including Transaortic Valve replacement (TAVR) planning and follow up examinations where the valve leaflets are seen in excellent detail. In cases with mechanical valves, PIQE provides superior detail of the valve compared to other reconstructions (Figure 4).

A list of scientific evidence on PIQE can be found at the end of this paper.

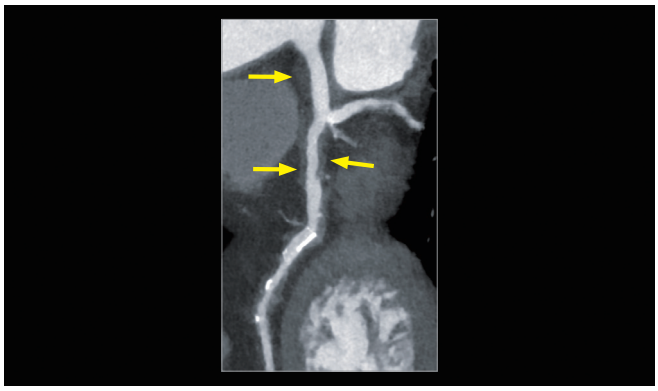

Figure 3: Positive remodeling clearly seen with no loss of low contrast detectability



Figure 4: Mechanical aortic valve leaflets clearly seen with PIQE 1024

Testimonials



"PIQE's visual clarity with reduced image noise and definition of fine cardiac anatomic structures improves the time spent evaluating especially challenging CTA examinations. The improved resolution seen with PIQE enhances characterization of plaque burden that might have been lost in image noise. It also increases our confidence to report coronary artery disease that previously may not have been observed such as luminal irregularities or spotty calcification."

Dr. Marcus Chen
National Heart, Lung & Blood Institute National Institutes of Health, USA

"Having the ability to achieve Ultra-High Resolution CT images from our routine cardiac CTA examinations is really where AI delivers. This impressive upgrade adds diagnostic value in cardiac imaging, not only in CAD but also in structural and aortic diseases."



Prof. Mickaël Ohana
Nouvel Hopital Civil, Strasbourg University Hospital, France



"PIQE offers higher spatial resolution and lower image noise compared to conventional reconstruction methods like hybrid IR, model-based IR, and DLR. In cardiac CT, PIQE enables clearer visualization of small atherosclerotic plaques and calcifications, facilitating the evaluation of plaque characteristics compared to other reconstruction techniques. Additionally, the use of PIQE effectively reduces blooming artifacts from stents, resulting in sharper identification of the stent struts and a clearer visualization of the vessel lumen. PIQE is considered a groundbreaking technology that should be widely implemented across various areas of the body."

Dr. Fuminari Tatsugami
Hiroshima University, Japan

PIQE 1024 Matrix training principles

The PIQE reconstruction algorithm features a next generation, three-dimensional neural network trained to identify and preserve signal features, both in-plane and longitudinally, throughout the cardiac volume dataset. Trained on high quality cardiac cases acquired on clinically operating Aquilion Precision systems, PIQE optimizes spatial resolution for clinically relevant tasks and realistic field-of-views. PIQE's three-dimensional learning also helps ensure continuity of small, longitudinally running vessels, which are often obscured by conventional reconstruction algorithms[6].

The training cases are acquired with the Aquilion Precision's Super High Resolution (SHR) mode that yields 0.15 mm anatomical detail. The SHR data is reconstructed with AiCE DLR which implicitly contains all the advanced models of MBIR. In addition to UHR mode, the Aquilion Precision also has Normal Resolution (NR) mode that combines detector channels to generate conventional resolution images in-plane and 0.5 mm nominal slice width equivalent to Aquilion ONE / PRISM Edition and Aquilion ONE / INSIGHT Edition. Raw data acquired in UHR mode can be reconstructed through a down-sampling algorithm to yield simulated Normal Resolution images, that have been demonstrated to be equivalent to true Normal Resolution images[1]. With this approach, both UHR and NR images can be produced from a single acquisition. As a result, pairs of UHR and simulated NR images have perfect spatial alignment, ideal for training a neural network. Simulated NR images are input to the neutral network and the corresponding UHR images are used as the gold standard target images. The neural network learns to maximize the inherent resolution possible with NR images and even enhance resolution further, while decreasing noise[6] (Figure 5).

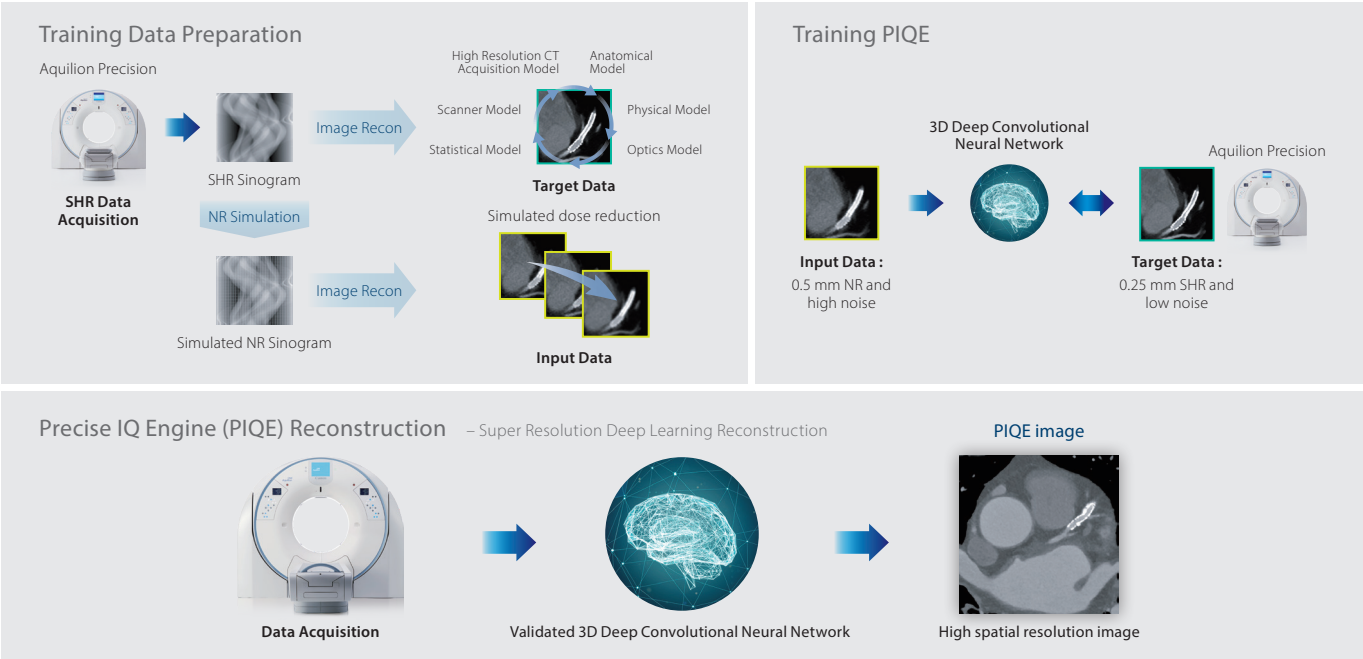

Figure 5: Training of PIQE network. Training data is prepared by down-sampling Precision UHR data. The network is trained using UHR data paired with down sampled, simulated NR data and actual UHR data. Once trained the network is validated and applied to the image reconstruction where it does not continue to learn.

The neural network behind PIQE does not learn features solely in the axial plane but rather in three dimensions, meaning signal features are identified and preserved in all three planes. This makes PIQE well-suited for cardiac exams, which are usually reviewed in MPR and curved planes[6] (Figure 6).

PIQE reconstructions are available in both 512 and 1024 matrix, with 1024 matrix providing superior resolution with no loss of reconstruction speed.

The authors were all involved in the initial evaluation and optimization of PIQE 1024 in close collaboration with the engineers at Canon Medical and they have shared a selection of cases that highlight the clinical benefits of PIQE 1024 in cardiac CT.

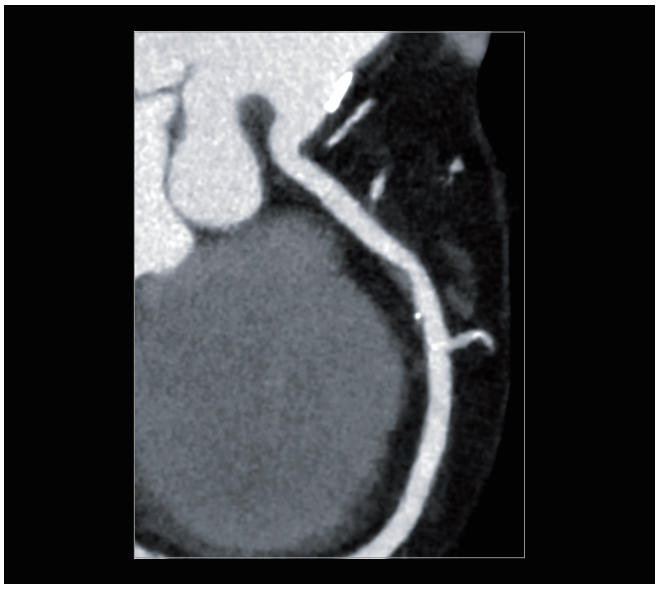

Figure 6: PIQE 1024 is trained to learn anatomical detail in 3 dimentions making it suited for high-quality curved MPR views

Stenosis in the right coronary artery (RCA)

Dr. Tatsugami, Hiroshima University, Japan

Patient History

This 73-year-old man presented with typical angina pectoris and a heart rate of 60 bpm. A coronary CTA was requested.

Results

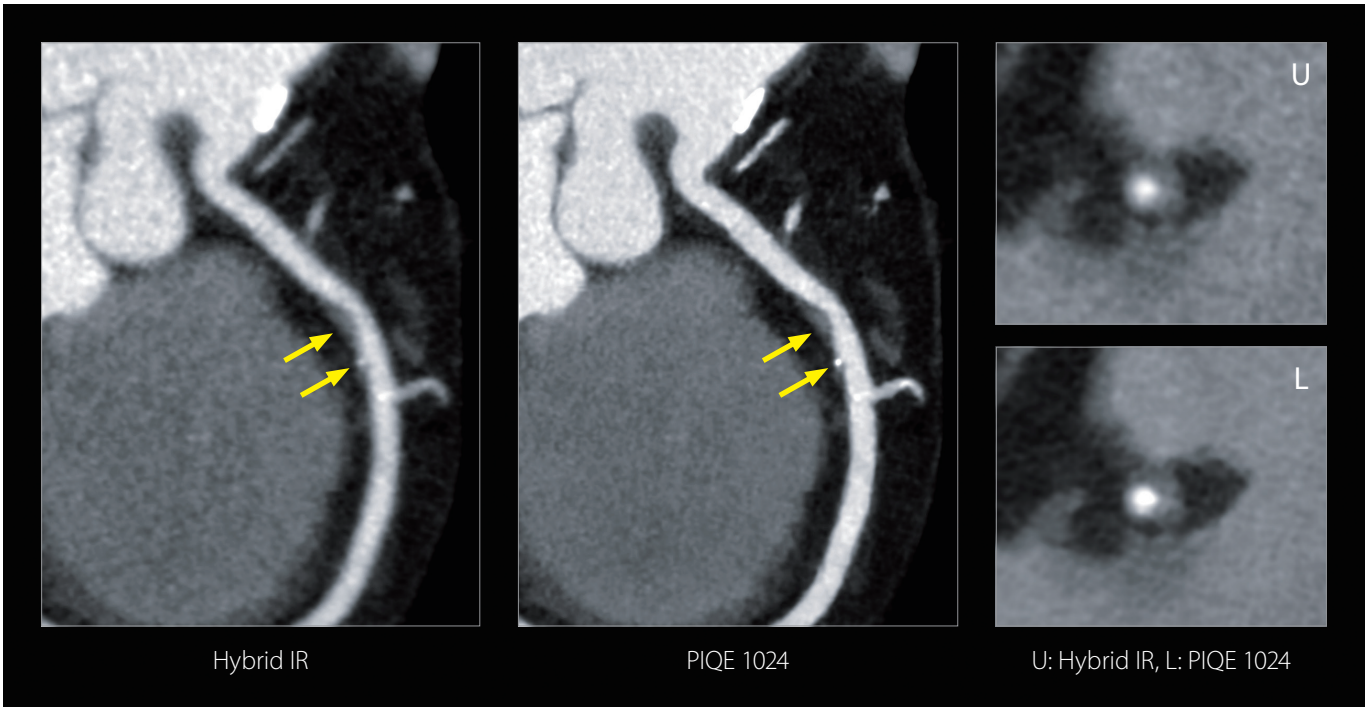

A mild stenosis of CAD-RADs 2 (25-49%) is seen in the proximal segment of the right coronary artery. Non-calcified plaque is identified at the stenotic site. A small calcification is seen immediately distal to the stenosis.

Clinical Benefit

The spotty calcification are described as high risk plaque features. PIQE 1024 may provide identification of micro calcifications beyond the resolution of current CT scanners.

Acquisition

Scan Parameters: One beat volume scan, exposure window 40-80%

Vulnerable plaque in the left circumflex artery (LCx)

Dr. Chen, National Institutes of Health, USA

Patient History

This 60-year-old man with BMI 29.4 and a history of an RCA stent presented with recent onset of chest pain. A Coronary CTA was requested.

Results

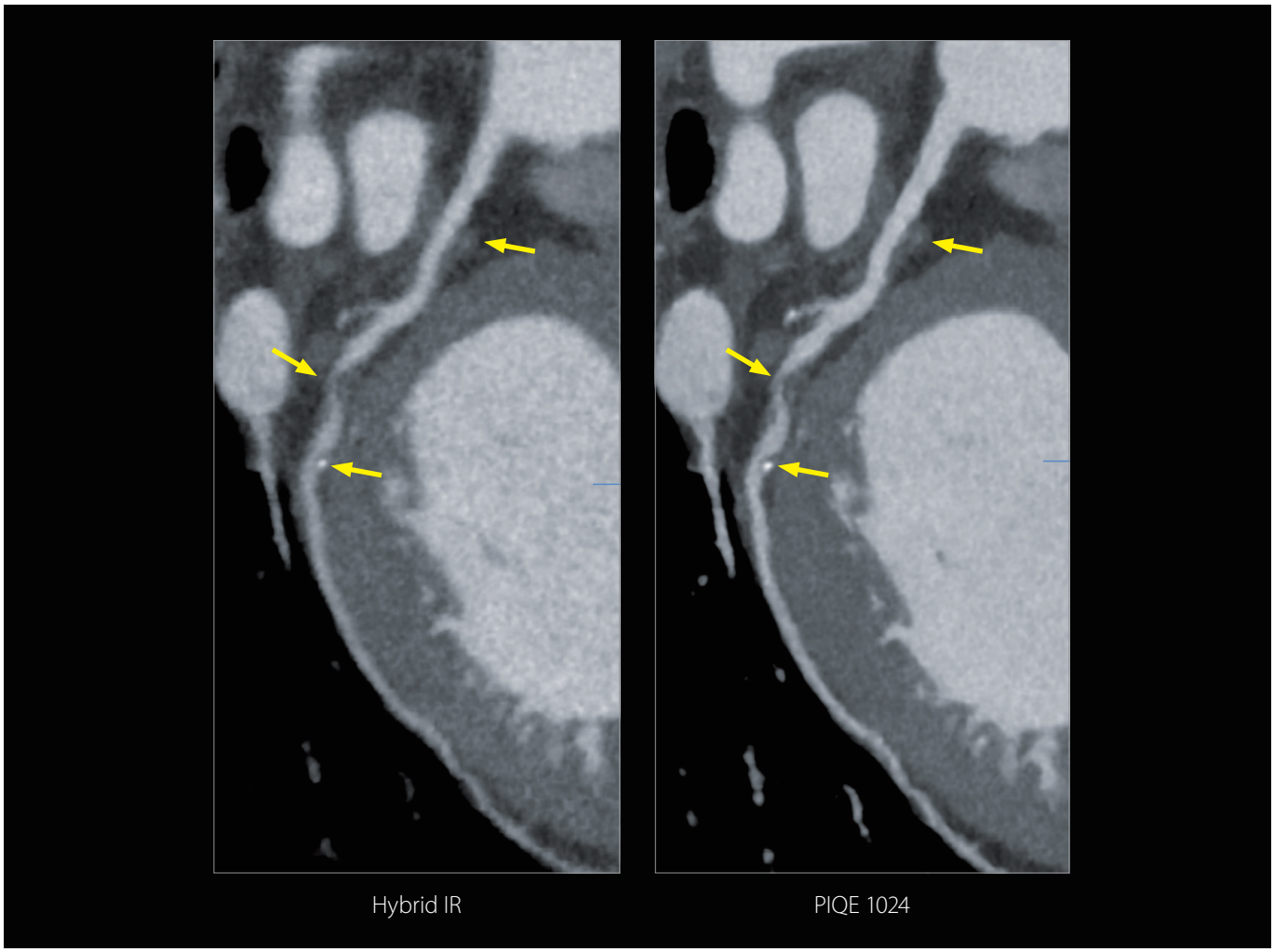

In the LCx there is a non-calcified severe (>70%) stenosis with outward/positive remodeling of the mid vessel. This stenosis is approximately 10 mm before the first obtuse marginal branch. There is a small, calcified plaque at the origin of the first obtuse marginal vessel.

Clinical Benefit

The positive remodeling and non-calcified plaque can be more easily appreciated on the PIQE 1024 images compared to the hybrid IR image. This is essential for a suitable assessment of positive remodeling, which is a marker of plaque vulnerability.

Acquisition

Scan Parameters:	One beat volume scan, exposure window 70-80%, 120 kV, SURE Exposure
CTDI vol:	10.9 mGy
DLP:	130.3 mGy·cm
Effective Dose:	1.82 mSv

Left anterior descending artery (LAD) non-calcified plaque and correlation with invasive coronary angiogram

Prof. Ohana, Strasbourg University Hospital, France

Patient History

This 67-year-old woman with a BMI 28 and a heart rate of 76 bpm presented with a history of angina. The Calcium Score scan was within normal range with an Agatston score of 68. A CTA was requested to investigate the cause of angina.

Results

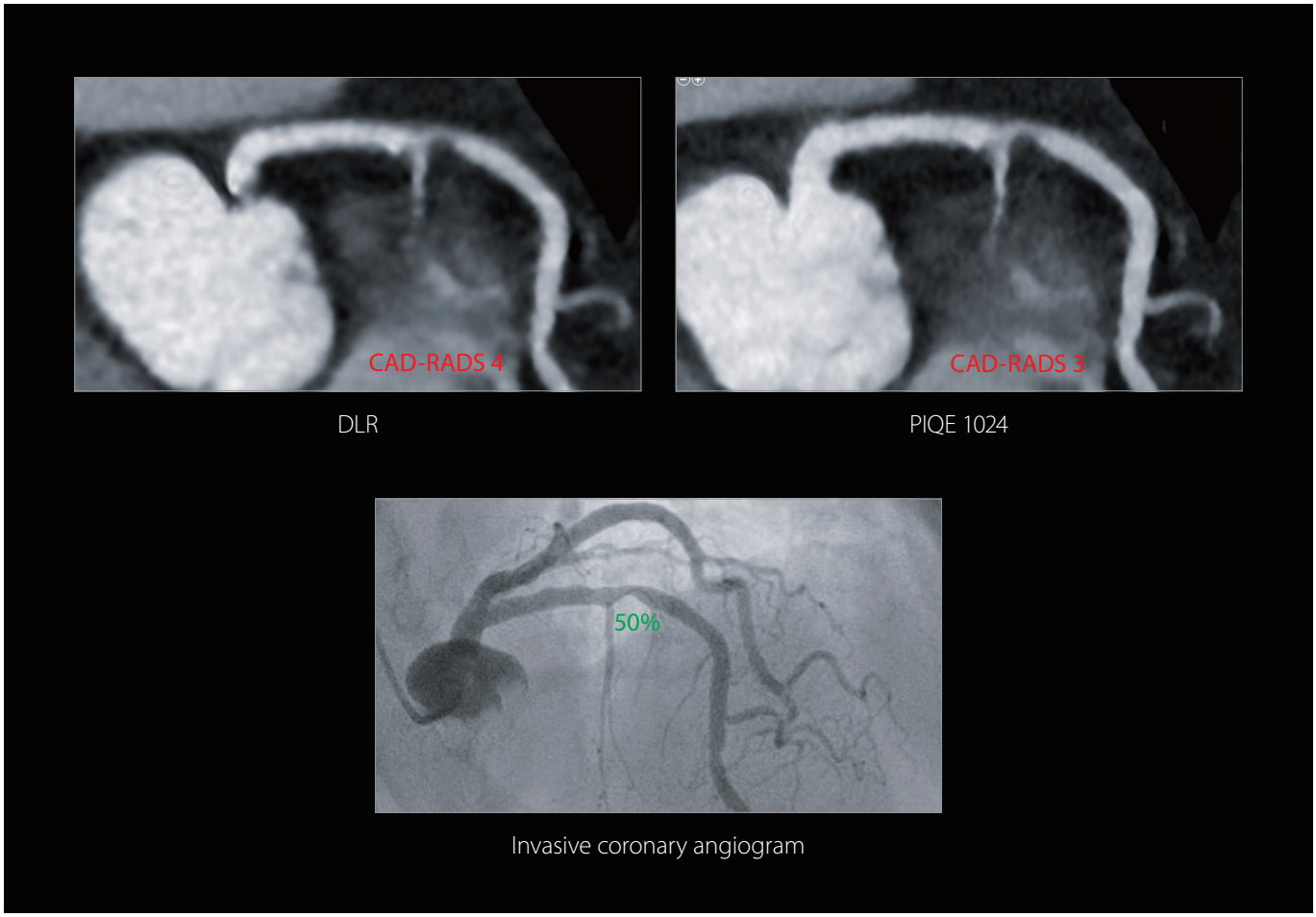

DLR | PIQE 1024

Invasive coronary angiogram

In the mid LAD there is a non-calcified plaque with positive remodeling. The residual lumen can be seen better with the PIQE 1024 reconstruction. With the DLR reconstruction, this stenosis was evaluated as severe (>70%) with a CAD-RADs 4 score. Using the PIQE 1024 images, this stenosis was evaluated as moderate (50-69%) with a CAD-RADs 3 score, which was comparable to the findings in the invasive coronary angiogram (50% stenosis).

Clinical Benefit

PIQE 1024 provides a CAD-RADs result comparable to the stenosis measurement calculated on the invasive coronary angiogram. This is essential for the accurate assessment of the severity of the stenosis.

Acquisition

Scan Parameters:	One beat volume scan, exposure window 30-80%, 100 kV, SURE Exposure
CTDI vol:	6.2 mGy
DLP:	99.5 mGy·cm
Effective Dose:	1.3 mSv

Napkin-Ring Sign in the first diagonal vessel

Dr. Tatsugami, Hiroshima University, Japan

Patient History

This 60-year-old man with a BMI 29 and heart rate of 61 bpm had a history of acute myocardial infarction and a previous revascularization procedure. As a follow-up, CT was performed for coronary artery evaluation.

Results

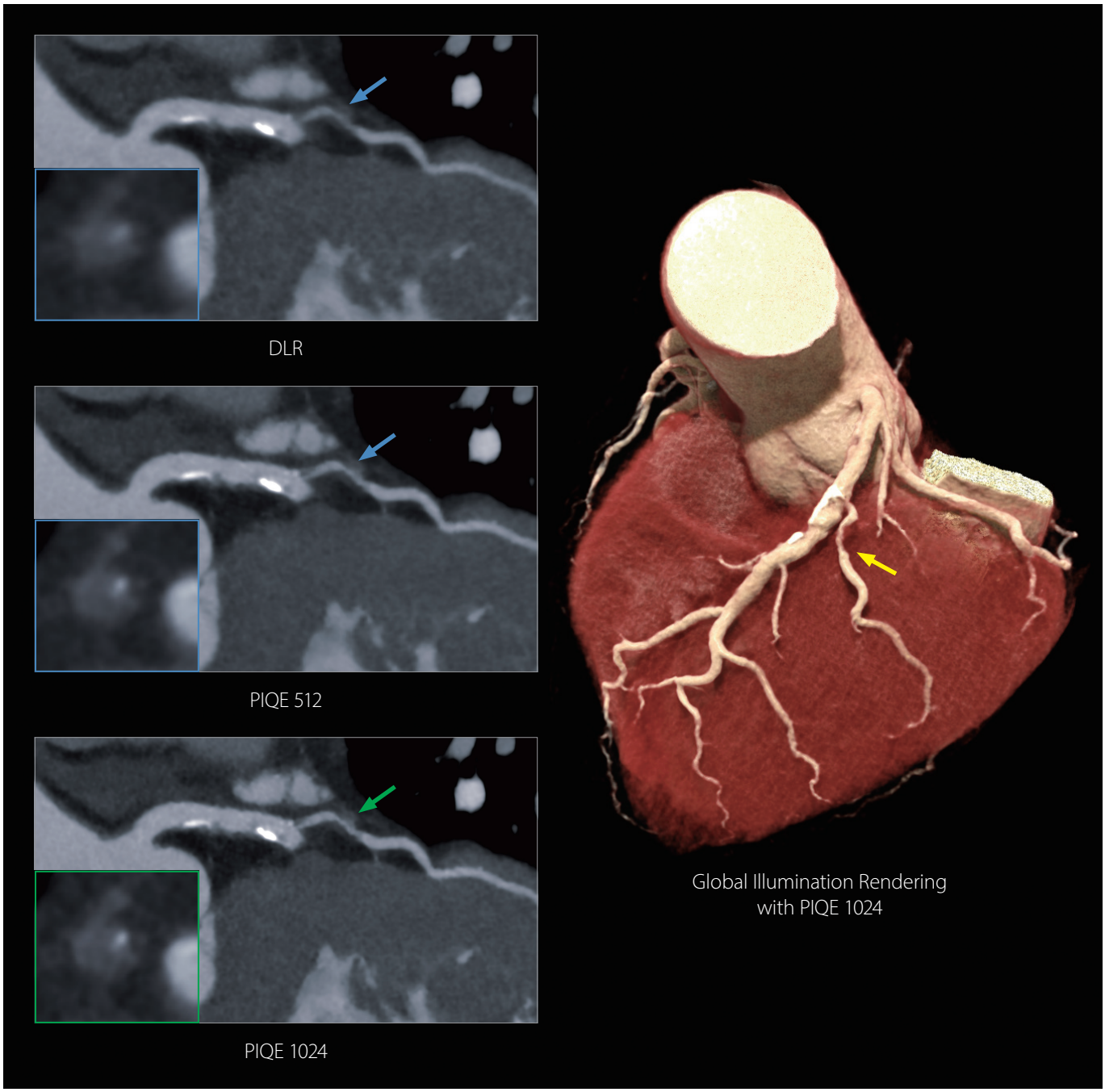

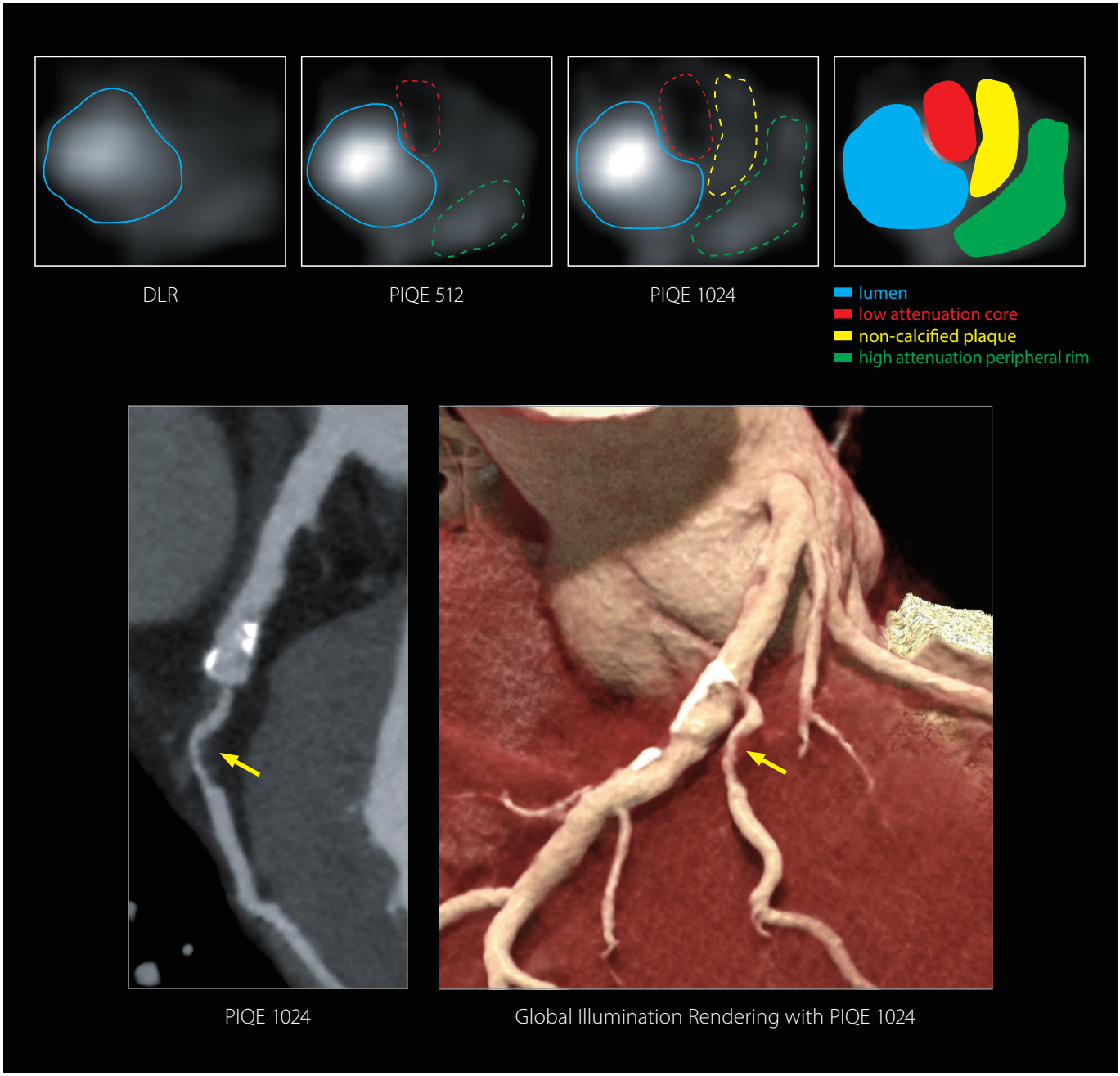

The D1 shows a non-calcified plaque causing a stenosis scored as CAD-RADs 3 (50-69% stenosis). It is very challenging to confirm whether there is a napkin-ring sign in the DLR and PIQE 512 images. However, the PIQE 1024 images clearly shows a napkin-ring sign.

Clinical Benefit

The unique combination of high resolution, low contrast detectability and low noise enabled by PIQE 1024 makes it possible to identify vulnerable plaques with the napkin-ring sign. Therefore, PIQE 1024 could help to identify coronary artery disease in patients at high risk of future acute coronary syndrome events.

Acquisition

Scan Parameters: Full beat volume scan, 120 kV, SURE Exposure

Large Positive Remodeling of Plaque in LAD

Dr. Chen, National Institutes of Health, USA

Patient History

This 60-year-old man with BMI 31.3 was asymptomatic. A cardiac CTA was requested for screening for coronary artery disease.

Results

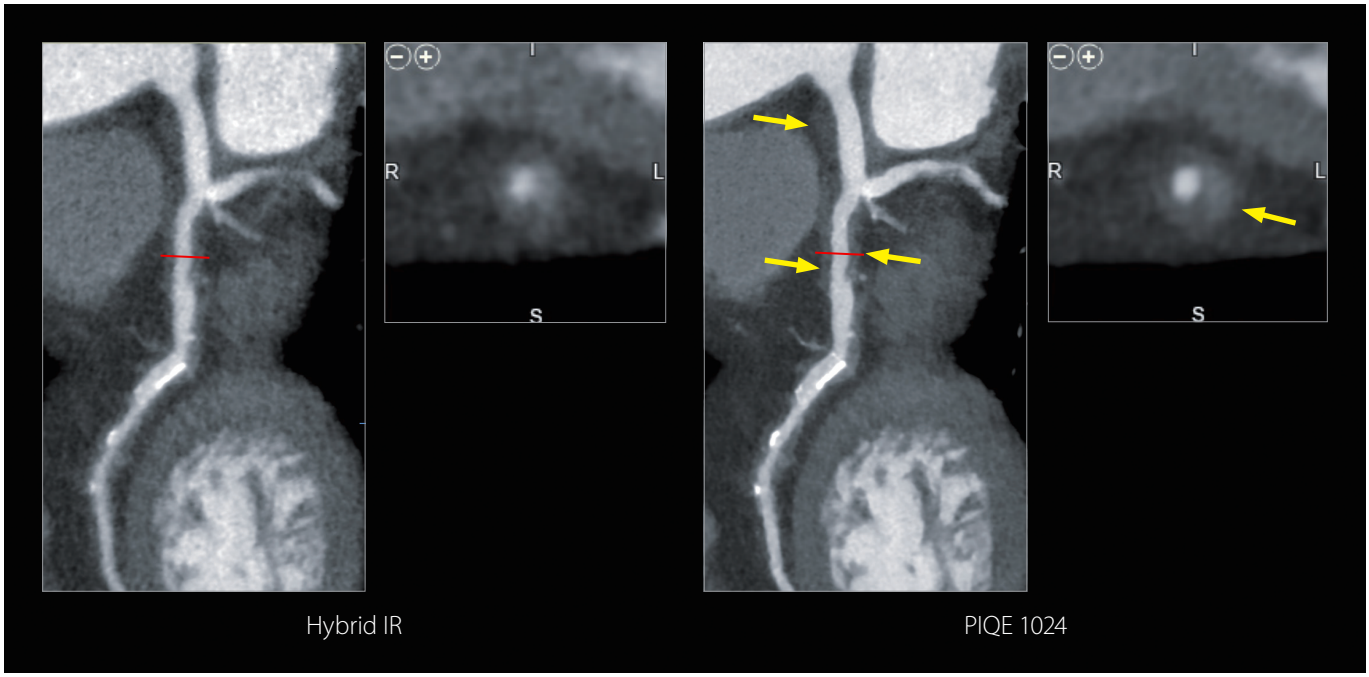

In the LAD, non-calcified plaque is seen concentrically around the vessel with significant positive remodeling resulting in minimal luminal narrowing. The plaque has an overall length of approximately 27 mm. The mid LAD has a calcified plaque causing mild (25-49%) stenosis followed by a second predominately non-calcified plaque region with positive remodeling resulting in minimal (<25%) luminal narrowing.

Clinical Benefit

The positive remodeling is an important plaque feature for the identification of vulnerable plaque. In this case, PIQE 1024 is a reliable technique to assess the extent of the positive remodeling.

Acquisition

Scan Parameters:	One beat volume scan, exposure window 70-80%, 120 kV, SURE Exposure
CTDI vol:	14.5 mGy
DLP:	173.8 mGy·cm
Effective Dose:	2.43 mSv

Mixed plaque in the RCA

Dr. Tatsugami, Hiroshima University, Japan

Patient History

This 73-year-old woman presented with a history of myocardial infarction and a heart rate of 59 bpm. This patient had a chest lead V2-6 negative T wave appearance. The Calcium Score scan showed severe coronary artery calcification with an Agatston score of 954. A cardiac CTA was requested to evaluate the coronary arteries.

Results

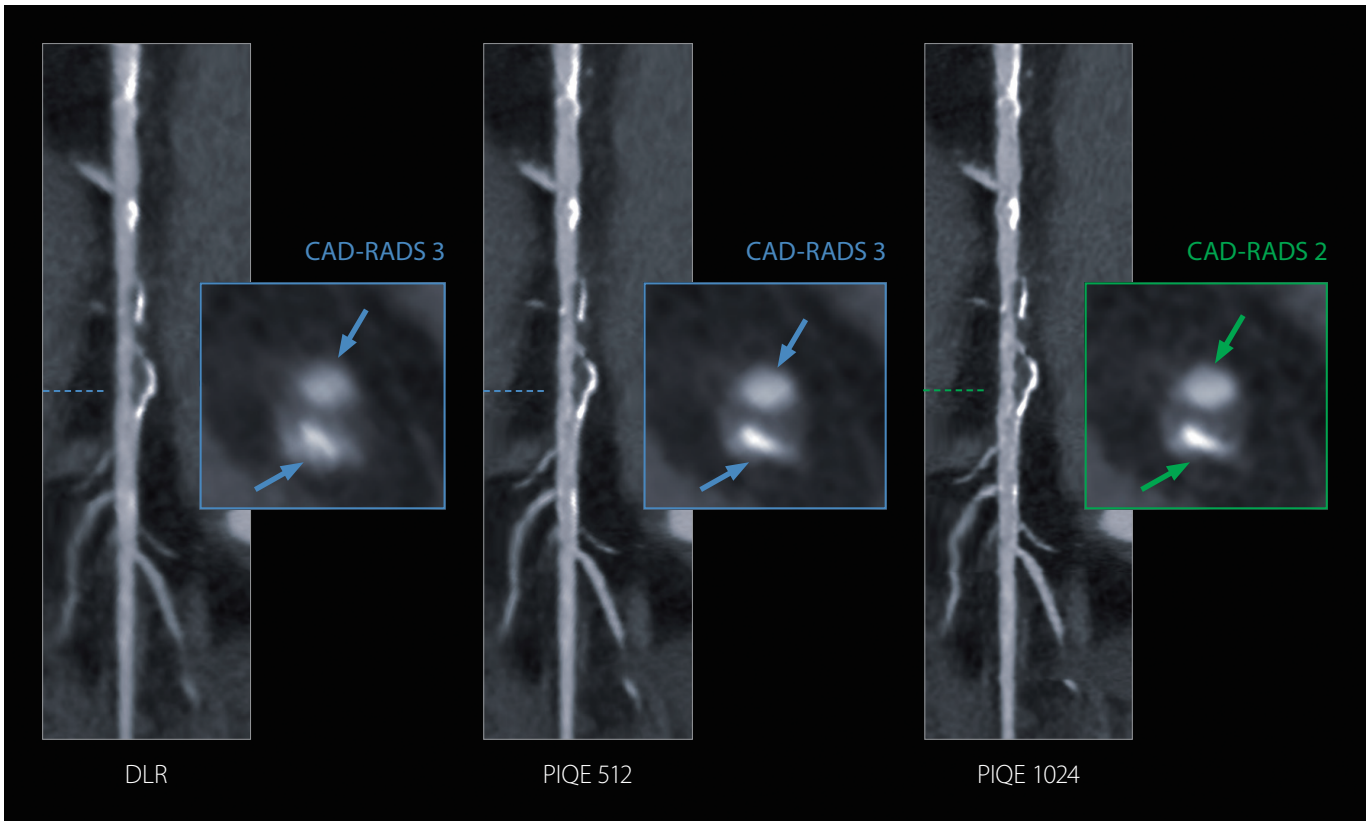

With the normal resolution DLR and PIQE 512 images, this stenosis was graded as moderate with a CAD-RADs 3 score (50-69% stenosis). The visualization of the contours of the non-calcified plaque and the residual lumen were clearly improved with the PIQE 1024 image. In addition, the calcified component of this mixed plaque has sharper boundaries and better delineation in the PIQE 1024 cross-sectional images compared to other reconstructions. This stenosis grading was reduced in the PIQE 1024 reconstruction to a mild stenosis with a CAD-RADs 2 score (25-49% stenosis).

Clinical Benefit

In this case, the increased resolution of PIQE 1024 improves the accuracy of CAD-RADs scorings.

Acquisition

Scan Parameters:	Full beat volume scan, 120 kV, SURE Exposure
CTDI vol.:	12.2 mGy
DLP:	195.5 mGy·cm
Effective Dose:	2.7 mSv

LAD calcified plaque with high calcium score

Prof. Ohana, Strasbourg University Hospital, France

Patient History

This 82-year-old patient with a prior diagnosis of COVID-19 underwent a chest CT scan which demonstrated severe coronary calcifications. The patient was referred to the cardiologist who requested a calcium score and a coronary CTA scan due to non-specific ECG changes. The patient's heart rate was 70 bpm at the time of scan.

Results

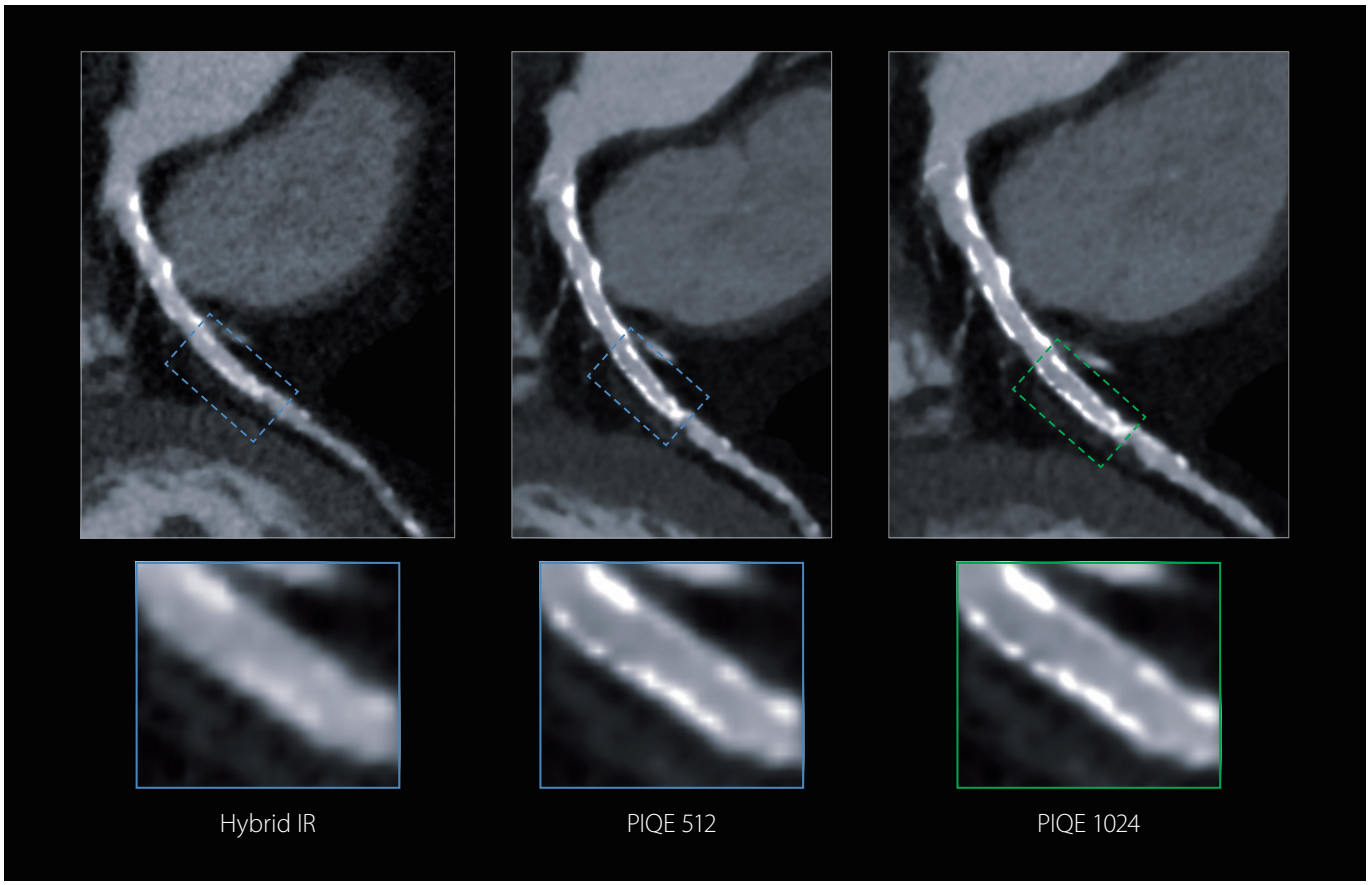

The calcium score scan showed extensive coronary artery disease (CAD) with an Agatston score of 2118. In the CCTA scan, the Left Main coronary artery (LM) and the proximal and mid-segments of the Left Anterior Descending artery (LAD) show significant wall calcifications with 25-49% stenosis in all these segments.

Clinical Benefit

PIQE 1024 provides better depiction of the vessel lumen which is sharper and less noisy compared to other reconstructions. In this patient, the increased spatial resolution resulted in less blooming artifacts, allowing a more confident assessment of the lumen patency even in the presence of circumferential calcified plaques.

Acquisition

Scan Parameters:	One beat volume scan, exposure window 30-80%, 100 kV, SURE Exposure
CTDI vol:	11.1 mGy
DLP:	177.2 mGy·cm
Effective Dose:	2.48 mSv

RCA Stent

Dr. Chen, National Institutes of Health, USA

Patient History

This 60-year-old man with BMI 29.3 and a history of an RCA stent presented with recent onset of chest pain. A Coronary CTA was requested.

Results

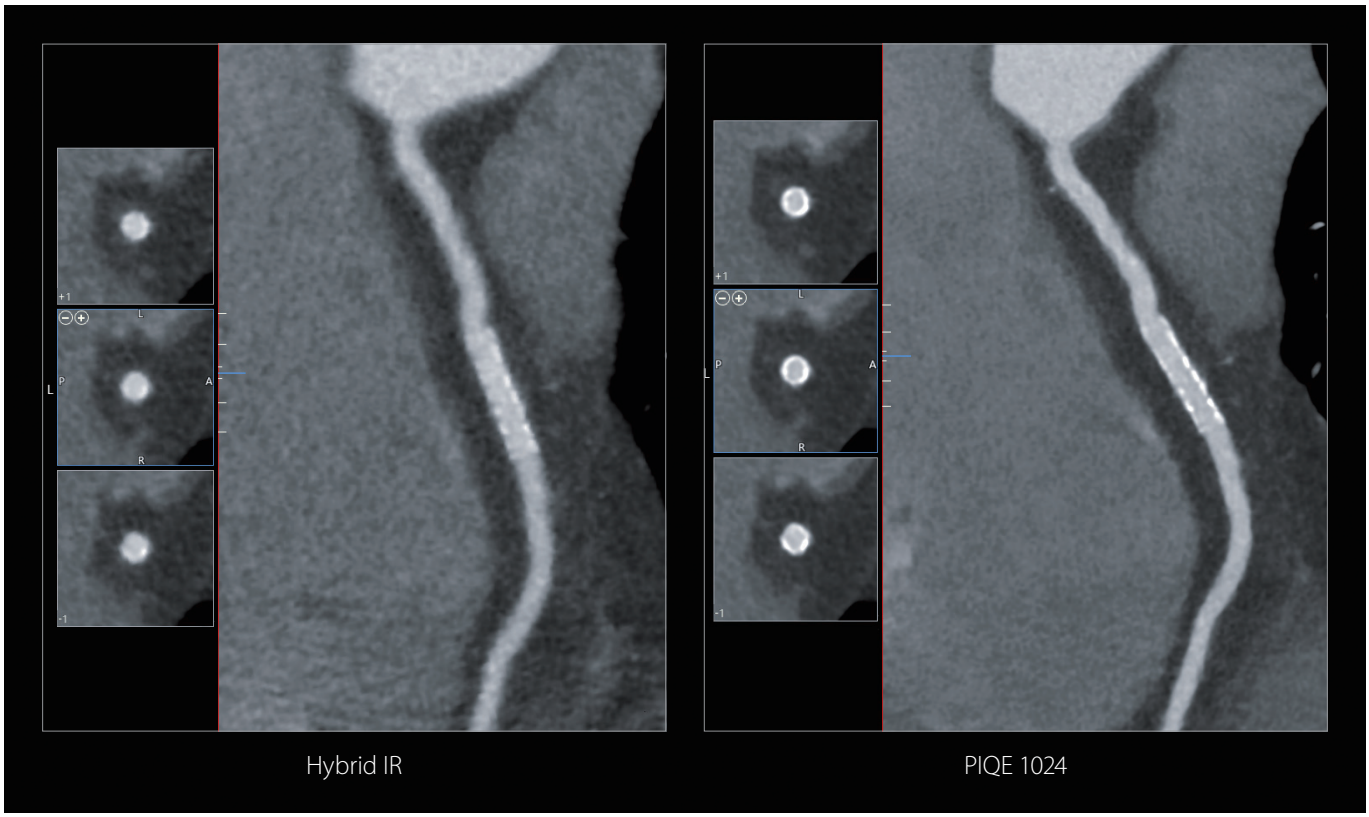

The stent and lumen can be more clearly seen on the PIQE 1024 images compared to Hybrid IR. The PIQE 1024 images show a patent stent in the RCA with no in-stent restenosis.

Clinical Benefit

The stent struts can be more clearly identified on the PIQE 1024 images. PIQE 1024 reduces the blooming artifact from the stent struts providing better visualization of the stent and lumen. This is important for a reliable visualization of in-stent restenosis.

Acquisition

Scan Parameters:	One beat volume scan, exposure window 70-80%, 120 kV, SURE Exposure
CTDI vol:	10.9 mGy
DLP:	130.3 mGy·cm
Effective Dose:	1.82 mSv

Stent in the LAD

Dr. Tatsugami, Hiroshima University, Japan

Patient History

This 69-year-old man underwent a Coronary CTA following PCI. The Patient's heart rate was 60 bpm.

Results

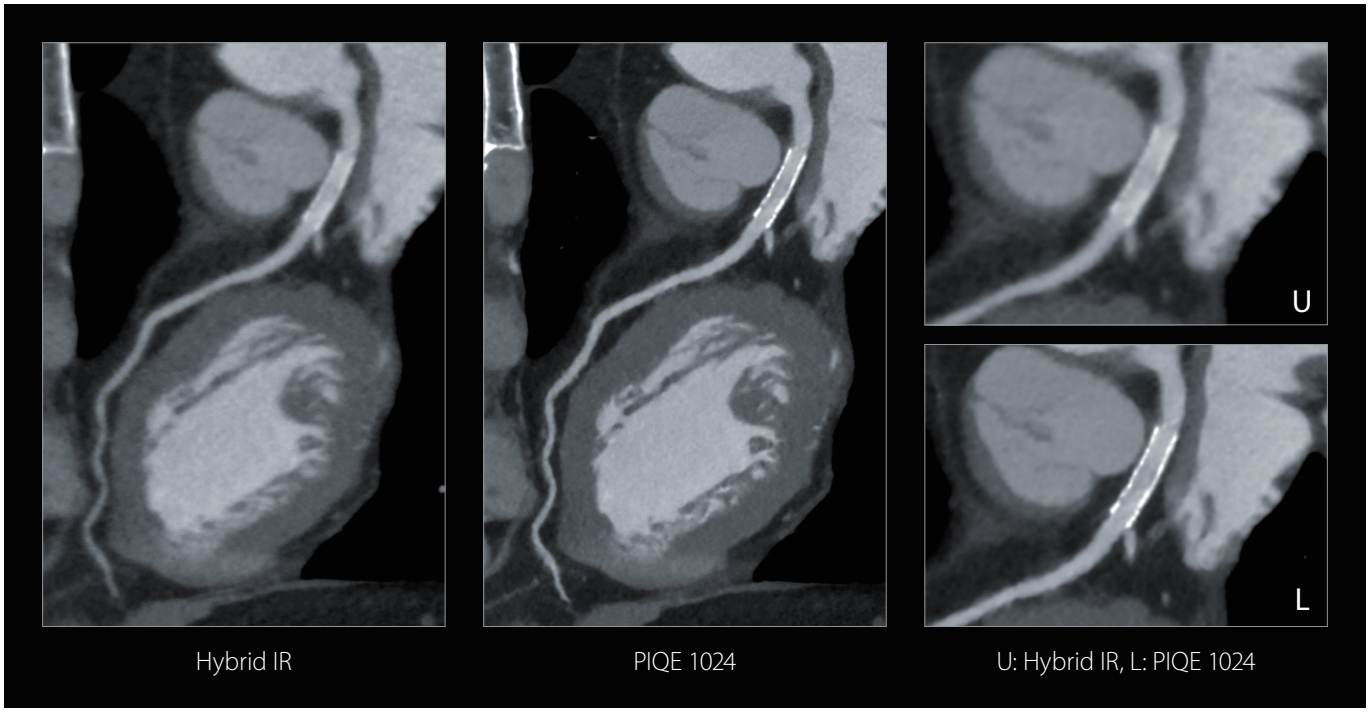

A stent is seen in the proximal left anterior descending coronary artery. The stent struts on the PIQE 1024 image are sharper than on the Hybrid IR image.

Clinical Benefit

Increased spatial resolution of stents allows clearer visualization of the lumen which is especially important in the evaluation of in-stent re-stenosis.

Acquisition

Scan Parameters: One beat volume scan, exposure window 40-80%
Effective Dose: 5.0 mSv

Post-op calcifications around an aortic prosthesis

Prof. Ohana, Strasbourg University Hospital, France

Patient History

This 68-year-old man with a BMI 30 and heart rate of 72 bpm had a history of post aorto-bi-iliac bypass stroke and a mechanical aortic valve. This patient underwent TTE, which indicated an increase in the gradient. A cardiac CTA was requested for a suspected valve thrombus.

Results

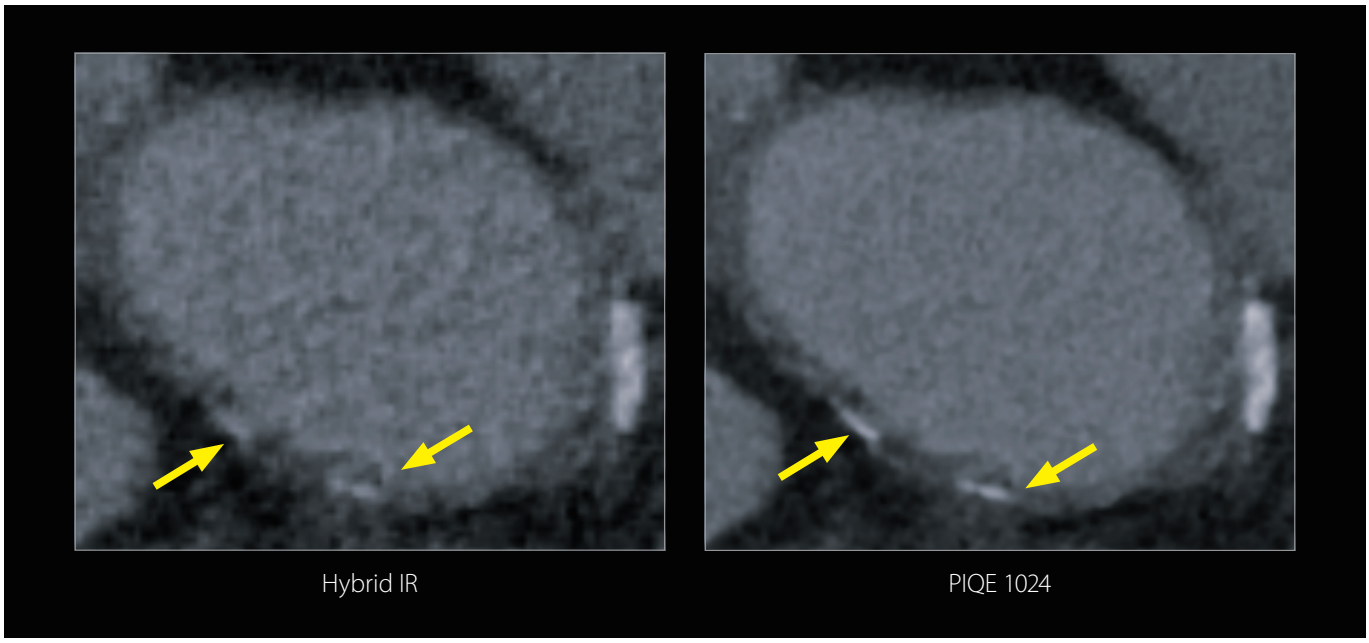

It is very challenging to depict the subtle low-density calcifications around the aortic prosthesis on the Hybrid IR reconstruction whereas the increased spatial resolution with PIQE 1024 matrix enables a perfect visualization of these post-op calcifications.

Clinical Benefit

PIQE 1024 increases the conspicuity of calcifications, which is clinically useful for enhancing the detection of faint or subtle low-density calcifications.

Acquisition

Scan Parameters:	Full beat volume scan, 120 kV, SURE Exposure
CTDI vol:	24.9 mGy
DLP:	398 mGy·cm
Effective Dose:	5.5 mSv

High resolution 4D aortic valve evaluation

Prof. Ohana, Strasbourg University Hospital , France

Patient History

This 64-year-old man with a heart rate of 51 bpm and a history of cardiac disease, smoking, family history and an ascending aortic aneurysm, underwent screening for ischemic heart disease. A cardiac CTA was requested to evaluate coronary arteries and for the assessment of the ascending aortic aneurysm. The aortic valve was also evaluated.

Results

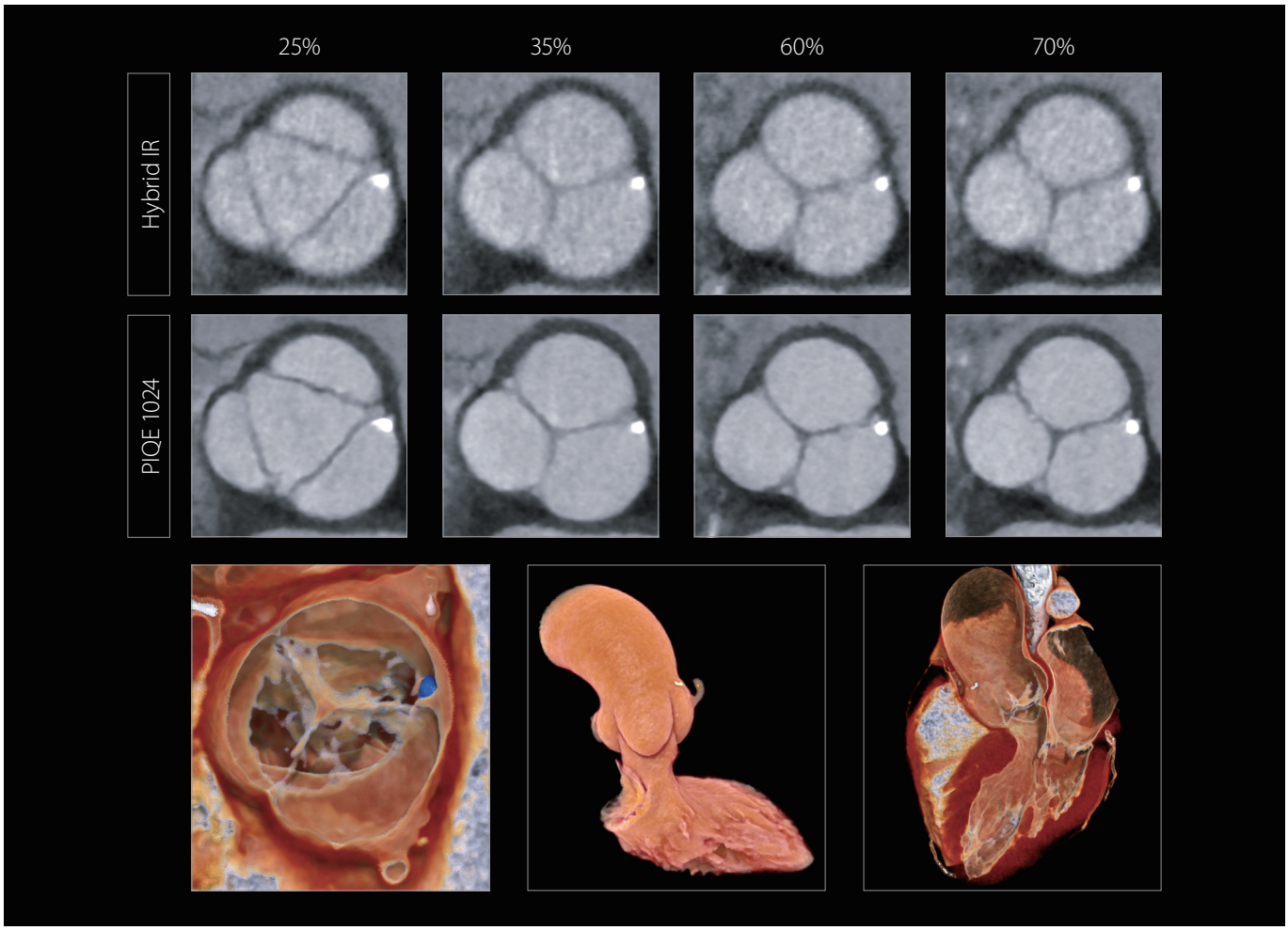

The clear delineation and sharpness of the aortic valve leaflets with PIQE 1024 outperforms the hybrid IR reconstruction. The opening and closing of the aortic valve leaflets can be clearly confirmed with the PIQE 1024 multiphase images. This tricuspid aortic valve shows calcification on the left cusp but without severe aortic stenosis.

Clinical Benefit

With its high spatial resolution, PIQE 1024 provides excellent delineation of the aortic valve leaflets. This can help to improve diagnostic accuracy for the aortic valve evaluation, which can be very beneficial in the planning of transcatheter aortic valve replacement (TAVR).

Acquisition

Scan Parameters:	Full beat volume scan, 100 kV, SURE Exposure
CTDI vol.:	22 mGy
DLP:	351.7 mGy·cm
Effective Dose:	4.9 mSv

Mechanical aortic valve

Prof. Ohana, Strasbourg University Hospital, France

Patient History

This 68-year-old man had a history of post aorto-bi-iliac bypass stroke and a mechanical aortic valve. This patient underwent TTE, which indicated an increase in the gradient. A cardiac CTA was requested for a suspected valve thrombus. The patient's BMI was 32 and heart rate was 70 bpm at the time of scan.

Results



The delineation and sharpness of the contours of the mechanical valve with PIQE 1024 outperforms all other reconstruction. The opening and closing of the symmetrical leaflets of the aortic valve can be clearly confirmed with the PIQE 1024 images. There is no mechanical aortic valve abnormality, especially no thrombus.

Clinical Benefit

PIQE 1024 provides excellent delineation and high spatial resolution of the prosthetic valve. It can help to enhance diagnostic accuracy and assessment of prosthetic aortic valve dysfunction.

Acquisition

Scan Parameters:	Full beat volume scan, 120 kV, SURE Exposure
CTDI vol:	24.9 mGy
DLP:	398 mGy·cm
Effective Dose:	5.5 mSv

Conclusion

PIQE brings excellent spatial resolution and reduced noise within a single rotation cardiac scan while maintaining low contrast detectability and with no additional radiation dose to the patient. PIQE enables more accurate CAD-RADs scoring, improved visualization of non-calcified plaque, reduced blooming artifact from calcium and stents, improved evaluation of stent patency, excellent valve leaflet definition and accurate TAVR planning.

The cases in this white paper represent the full range of clinical value of PIQE 1024 for cardiac applications.

References

1. IHME, Global Burden of Disease (2019).
2. Miller JM, Rochitte CE, Dewey M, et al, Diagnostic performance of coronary angiography by 64-row CT, N Engl J Med. 2008 Nov 27;359(22):2324-36.
3. Jean-Philippe Collet, Holger Thiele, Emanuele Barbato, et al, 2020 ESC Guidelines for the management of acute coronary syndromes in patients presenting without persistent ST-segment elevation, Eur Heart J. 2021 Apr 7;42(14):1289-1367.
4. Gulati M, Levy PD, Mukherjee D, et al, 2021 AHA/ACC/ASE/CHEST/SAEM/SCCT/SCMR Guideline for the Evaluation and Diagnosis of Chest Pain: A Report of the American College of Cardiology/American Heart Association Joint Committee on Clinical Practice Guidelines., J Am Coll Cardiol. 2021 Nov 30;78(22):e187-e285.
5. Cury R, Leipsic J, Abbara S, Achenbach S, et al, JCCT, 2022, 2:536-557
6. Boedeker K, 2022, PIQE White Paper, Canon Medical.

PIQE Scientific Evidence

Publications

Kawai H, Motoyama S, Sarai M, Sato Y, Matsuyama T, Matsumoto R, Takahashi H, Katagata A, Kataoka Y, Ida Y, Muramatsu T, Ohno Y, Ozaki Y, Toyama H, Narula J, Izawa H. Coronary computed tomography angiographic detection of in-stent restenosis via deep learning reconstruction: a feasibility study. *Eur Radiol. 2023 Sep 6. doi: 10.1007/s00330-023-10110-7. Epub ahead of print. PMID: 37672056.*

- **Conclusion:** PIQE provides superior image quality and diagnostic accuracy for ISR, even with stents measuring < 3.0 mm in diameter.
- **Clinical relevance statement:** With improvements in the diagnostic accuracy of in-stent stenosis, CT angiography could become a gatekeeper for ICA in post-stenting cases, obviating ICA in many patients after recent stenting with infrequent ISR and allowing non-invasive ISR detection in the late phase.

Takafuji M, Kitagawa K, Mizutani S, Hamaguchi A, Kisou R, Iio K, Ichikawa K, Izumi D, Sakuma H. Super-Resolution Deep Learning Reconstruction for Improved Image Quality of Coronary CT Angiography. Radiol Cardiothorac Imaging. 2023 Aug 17;5(4):e230085. doi: 10.1148/ryct.230085. PMID: 37693207; PMCID: PMC10485715.

- **Conclusion:** SR-DLR improved vessel sharpness, image noise, and accuracy of coronary stenosis grading compared with the C-DLR technique.

Fuminari Tatsugami, Toru Higaki, Ikuo Kawashita, Wataru Fukumoto, Yuko Nakamura, Masakazu Matsuura, Tzu-Cheng Lee, Jian Zhou, Liang Cai, Toshiro Kitagawa, Yukiko Nakano, Kazuo Awai, Improvement of Spatial Resolution on Coronary CT Angiography by Using Super-Resolution Deep Learning Reconstruction, *Acad Radiol. 2023 Jan 19;S1076-6332(22)00700-0. doi: 10.1016/j.acra.2022.12.044.*

- **Conclusion:** SR-DLR was superior to hybrid IR with respect to the image noise, the sharpness of coronary artery margins, and plaque detectability.

Hideyuki Sato, Shinichiro Fujimoto, Nobuo Tomizawa, Hidekazu Inage, Takuya Yokota, Hikaru Kudo, Ruiheng Fan, Keiichi Kawamoto, Yuri Honda, Takayuki Kobayashi, Tohru Minamino, Yosuke Kogure, Impact of a Deep Learning-based Super-resolution Image Reconstruction Technique on High-contrast Computed Tomography: A Phantom Study, *Acad Radiol. 2023 Jan 21;S1076-6332(22)00696-1. doi: 10.1016/j.acra.2022.12.040.*

- **Conclusion:** The present results suggest that DLSRR can achieve greater noise reduction and improved spatial resolution in the high-contrast region compared with conventional DLR and iterative reconstruction techniques.

Makoto Orii, Misato Sone, Takeshi Osaki, Yuta Ueyama, Takuya Chiba, Tadashi Sasaki, Kunihiro Yoshioka Super-resolution deep learning reconstruction at coronary computed tomography angiography to evaluate the coronary arteries and in-stent lumen: An initial experience, *Research Square. DOI: https://doi.org/10.21203/rs.3.rs-1875541/v2*

- **Conclusion:** SR-DLR improves the image quality of the coronary arteries and in-stent lumen at CTA. Datasets reconstructed with SR-DLR empower the clinician with the high-contrast signal definition and reduce noise, relative to conventional MBIR.

Yasunori Nagayama, Takafumi Emoto, Hidetaka Hayashi, Masafumi Kidoh, Seitaro Oda, Takeshi Nakaura, Daisuke Sakabe, Yoshinori Funama, Noriaki Tabata, Masanobu Ishii, Kenshi Yamanaga, Koichiro Fujisue, Seiji Takashio, Eiichiro Yamamoto, Kenichi Tsujita, and Toshinori Hirai, Coronary Stent Evaluation by CTA: Image Quality Comparison Between Super-Resolution Deep-Learning Reconstruction and Other Reconstruction Algorithms, AJR, 2023, https://doi.org/10.2214/AJR.23.29506

- **Conclusion:** SR-DLR yielded improved delineation of the stent strut and in-stent lumen, with better image sharpness and less image noise and blooming artifacts, in comparison with HIR, MBIR, and NR-DLR.

Yasunori Nagayama, Takafumi Emoto, Yuki Kato, Masafumi Kidoh, Seitaro Oda, Daisuke Sakabe, Yoshinori Funama, Takeshi Nakaura, Hidetaka Hayashi, Sentaro Takada, Ryutaro Uchimura, Masahiro Hatemura, Kenichi Tsujita & Toshinori Hirai, Improving image quality with super-resolution deep-learning-based reconstruction in coronary CT angiography, European Radiology, 2023, https://doi.org/10.1007/s00330-023-09888-3

- **Conclusion:** SR-DLR considerably improved the subjective and objective image qualities and object detectability of CCTA relative to HIR, MBIR, and NR-DLR algorithms.

Presentations

RSNA 2023

Super-Resolution Deep Learning Reconstruction (DLR) vs. Conventional DLR vs. Hybrid-Type and Model-Based Iterative Reconstruction (IR): Comparison of Stenosis Evaluation Accuracy and CAD-RADS Classification on Coronary CT Angiography at In Vitro and In Vivo Studies, Takahiro Matsuyama, Yoshiharu Ohno, Tomoki Takahashi, Yuya Ito, Hirona Kimata, Kenji Fujii, Naruomi Akino, Hiroyuki Nagata, Hokuto Akamatsu, Ryota Hanaoka, Ryoichi Kato, Yoshiyuki Ozawa, Hiroshi Toyama

- **Conclusion:** SR-DLR has a potential to improve stenosis evaluation accuracy, stenosis confidence level and CAD-RADS classification on coronary ADCTA than others at in vitro and in vivo studies.

Coronary Artery Calcium Quantification with Super Resolution Deep-learning Reconstruction Algorithm: An Anthropomorphic Phantom Study, Shinsuke Shigematsu, Yasunori Nagayama, Takafumi Emoto, Daisuke Sakabe, Makoto Goto, Seitaro Oda, Masafumi Kidoh, Takeshi Nakaura, Toshinori Hirai

- **Conclusion:** SR-DLR can improve image quality and facilitate accurate CAC detection and quantification even at lower radiation doses, but its clinical application requires caution due to the deviation of the Agatston score from the conventional high-dose FBP setting.

SCCT 2023

Validation of new super resolution deep learning reconstruction for coronary artery calcium scoring, *John Schuzer, Chloe Steveson, Shirley Rollison, Kathie Bronson, Qiulin Tang, Chih-Chieh Liu, Jian Zhou, Steve Ross, Liang Cai, Zhou Yu, Marcus Chen*

- **Conclusion:** Newly introduced super resolution deep learning reconstructions (PIQE) provides excellent correlation of quantified risk stratification and classification compared with previous conventional reconstructions (FBP) but with reduced SNR and improved CNR.

ECR 2023

Super Resolution Deep Learning Reconstruction for Cardiac CT: upscale your game!; *M. Ohana, F. Tatsugami, A. Labani, W. Fukumoto, A. Taniguchi, K. Haioun, K. Awai, C. Roy,* https://epos.myesr.org/poster/esr/ecr2023/C-10591

- **Conclusion:** SR-DLR in - routine - cardiac CT in 2023 is an AI algorithm designed to enhance/increase CT image quality, is dedicated, for now, to cardiac CT, is usable without impact on workflow nor dosimetry. SR-DLR does increase the perceived IQ of coronary CTA. SR-DLR could carry a potential diagnostic impact, with possible better delineation of minimal lesions, possible better assessment of highly calcified vessels and possible better plaque quantification.

CT image reconstruction using super-resolution deep learning: Physical evaluation and clinical impact, *Tatsugami F, Higaki T, Kawashita I, Tsushima S, Fukumoto W, Nakamura Y, Mickaël Ohana, Awai K*

- **Conclusion:** SR-DLR has an attractive impact on clinical CT imaging. SR-DLR drastically reduces image noise as well as improves spatial resolution; it provides higher special resolution than MBIR and lower image noise than DLR. SR-DLR image has sharper vascular margins with fewer blooming artifacts and visualizes small structures more clearly. This reconstruction technique is expected to contribute to improving lesion detection.

Impact of super resolution deep learning reconstruction with 1024 matrix in potential CAD-RADS 3 lesions: retrospective analysis of 50 cases, *Mickaël Ohana, Fuminari Tatsugami, Aissam Labani, Wataru Fukumoto, Yuto Fuji, Soraya El Ghannudi, Akira Taniguchi, Karim Haioun, Kazuo Awai & Catherine Roy*

- **Conclusion:** The use of SR-DLR with 1024 matrix significantly modifies the way expert readers adjudicate potential intermediate stenosis on CTA. This effect tends towards downgrading of the lesion and appears statistically more pronounced in non-calcified or mixed plaques.

Super resolution-deep learning reconstruction (SR-DLR) on Coronary ADCT Angiography: Comparison of Image Quality and Stenosis Evaluation Accuracy with Hybrid-Type and Model-Based Iterative Reconstructions and Conventional Deep Learning Reconstruction, *Yoshiharu Ohno*

- **Conclusion:** SR-DLR can improve image noise, SNR, CNR, overall image quality and diagnostic confidence level at myocardia or vessels as compared with DLR, MBIR and hybrid-type IR at in vivo study.
- **Clinical Relevance/Application:** SR-DLR has a potential to improve stenosis evaluation accuracy, image quality and stenosis confidence level than others on cardiac ADCT.

RSNA 2022

S3A-SPCA-1 - Improvement of Coronary Stent CT Imaging with Super-Resolution Deep-Learning Reconstruction: An Initial In Vivo Experience, *Y. Nagayama*

- **Conclusions:** SR-DLR improves the objective and subjective qualities of coronary stent imaging compared with HIR, MBIR, and NR-DLR algorithms.
- **Clinical Relevance/Application:** Novel SR-DLR algorithm allows improvement of coronary stent evaluation because of excellent spatial resolution, lower blooming artifact, and stent-induced beam-hardening artifacts.

S3A-SPCA-4 - Super-Resolution Deep Learning Reconstruction for Cardiac CT: Comparison of Stenosis Evaluation Accuracy, Image Quality, Stenosis Confidence Level at Coronary Arteries and CAD-RADS Classification with Hybrid-Type and Model-Based Iterative Reconstructions and Deep Learning, *Yoshiharu Ohno*

- **Conclusions:** SR-DLR has a potential to improve stenosis evaluation accuracy, image quality and stenosis confidence level on cardiac CT than others at in vivo and in vitro studies.
- **Clinical Relevance/Application:** SR-DLR has a potential to improve stenosis evaluation accuracy, image quality and stenosis confidence level than others on cardiac ADCT.

M5A-SPPH-7 - Importance of Larger Reconstruction Matrix Sizes for Super-Resolution Deep Learning Reconstruction at In Vivo and In Vitro Studies, *Toru Higaki*

- **Conclusions:** To fully utilize the spatial resolution of SR-DLR, it is suitable to reconstruct images with 1024 matrices.
- **Clinical Relevance/Application:** The SR-DLR of 1024 matrix images provides higher spatial resolution, which is useful for the visualization of fine structures such as demonstration of plaques in the coronary artery, and fine lesions in diffuse lung disease.

R5B-SPPH-1 - Task-Based Image Quality Assessments of Super-Resolution Deep-Learning Reconstruction for Coronary CT Angiography, *Yasunori Nagayama*

- **Conclusions:** Compared with HIR, MBIR, and NR-DLR algorithms, newly introduced SR-DLR improved the task-based image quality and detectability for low- and high-contrast objects relevant to coronary CT angiography.
- **Clinical Relevance/Application:** SR-DLR provides CT images with excellent spatial resolution, preferable noise texture, and object detectability, potentially facilitating the interpretation of coronary artery diseases.

S3B-SPCA-2 - Efficacy of Super-Resolution Deep-Learning Reconstruction for the Assessments of Obstructive Coronary Artery Disease on Cardiac CT, *Y. Nagayama*

- **Conclusions:** SR-DLR considerably improves the subjective and objective image qualities and diagnostic confidence of CTA in patients with obstructive CAD.
- **Clinical Relevance/Application:** SR-DLR improves the spatial resolution while reducing noise and blooming, thereby allowing the accurate interpretation of CTA performed in patients with obstructive CAD.

ECR 2022

Can Super Resolution Deep Learning Reconstruction modify the atheroma burden in CAD-RAS 0-2 patients? *Mickaël Ohana, Fuminari Tatsugami, Aissam Labani, Wataru Fukumoto, Soraya El Ghannudi, Akira Taniguchi, Karim Haioun, Kazuo Awai & Catherine Roy*

- **Conclusions:** SR-DLR better identifies minimal non-obstructive coronary atherosclerosis compared to IR and DLR, which could better stratify patient's cardiovascular risk.

RPS 2103-5 - Image quality from super resolution deep learning reconstruction on coronary CT angiography, *J. Schuzer, T-C. Lee, J. Zhou, L. Cai, M. Matsuura, T. Nemoto, H. Taguchi, Y. Noshi, M. Y. Chen*

- **Conclusions:** PIQE has improved spatial resolution, noise characteristics, diagnostic confidence and image quality compared to conventional reconstruction.

Advanced physics-based image quality assessment of a commercial super resolution deep learning reconstruction algorithm for cardiac radiology applied to a wide volume computed tomography system, *Kirsten Boedeker, Los Angeles / US*

- **Conclusions:** PIQE SR-DLR improves spatial resolution relative to conventional reconstruction while providing equivalent or increased Low Contrast Detectability, reduced noise magnitude, equivalent noise texture.
- **Clinical Relevance:** PIQE SR-DLR offers the potential for improved diagnostic confidence and quantification of biomarkers.

AHA 2022

SU2282 / 2282 - Super Resolution Deep Learning Reconstruction for Detection of In-Stent Restenosis
Hideki Kawai, Sadako Motoyama, FUJITA HEALTH UNIVERSITY, Toyoake, Japan; Masayoshi Sarai, Yoshihiro Sato, Hiroshi Takahashi, Fujita Health Univ, Toyoake, Japan; Takashi Muramatsu, FUJITA HEALTH UNIVERSITY HOSPITAL, Toyoake; Jagat Narula, FUJITA HEALTH UNIVERSITY HOSPITAL, Toyoake, New York, NY; Hideo Izawa, FUJITA HEALTH UNIVERSITY, Toyoake, Japan

- **Conclusions:** PIQE provides superior image quality and diagnostic accuracy for ISR, even in stents with < 3.0 mm diameter.

RSNA 2021

SPR-PH-22 Noise Properties and Low Contrast False Positive and False Negative Assessment of A Super Resolution Deep Learning Reconstruction Algorithm Trained With Data From A Commercial High Resolution CT System, *Kirsten Lee Boedeker, PHD, Los Angeles, USA*

- **Conclusions:** SR-DLR has equivalent or improved noise and LCD properties to conventional reconstruction, including false positive and false negative fractions.
- **Clinical Relevance/Application:** The work addresses the robustness of noise properties of a new SR-DLR Cardiac CT reconstruction algorithm, a common clinical concern for adoption of machine learning based technology.

SDP-CA-23 Improvement of Spatial Resolution by Using Super-resolution Deep Learning Reconstruction at Coronary CT Angiography, *Fuminari Tatsugami, Hiroshima, Japan*

- **Conclusions:** The use of SR-DLR reduces image noise and improves spatial resolution at cardiac CT compared to conventional hybrid IR.
- **Clinical Relevance/Application:** A super-resolution deep learning reconstruction for conventional coronary CT images reduces image noise and improves spatial resolution.

PH04-B6 Performance Evaluation of a Super Resolution Deep Learning Reconstruction Algorithm Trained Using Data from A Commercial High Resolution CT System, *Kirsten Lee Boedeker, PHD, Los Angeles, USA*

- **Conclusions:** SR-DLR significantly improves spatial resolution, both in-plane and longitudinal, for a standard cardiac protocol, while maintaining equivalent or improved LCD and other image quality properties, relative to the other reconstruction methods.
- **Clinical Relevance/Application:** SR-DLR offers a significant improvement in spatial resolution for Cardiac CT, while maintaining LCD, offering the potential for improved diagnosis and quantification of biomarkers.

SDP-PH-11 Super-resolution Deep Learning Reconstruction At CT: A Phantom Study for Coronary CT Angiography, *Toru Higaki, PhD, Hiroshima, Japan*

- **Conclusions:** The SR-DLR improved not only spatial resolution but also image noise.
- **Clinical Relevance/Application:** The super-resolution deep learning reconstruction may improve the diagnostic ability of coronary CT angiography.

PHEE-10 Various Applications of Deep Learning-based Reconstruction At CT: Denoise, Dual-energy CT, And Super-resolution, *Toru Higaki, PhD, Hiroshima, Japan*

Canon
CANON INC.

30-2, Shimomaruko 3-chome, Ohta-ku, Tokyo 146-8501, Japan
Telephone: (81)-3-3758-2111
©CANON INC. 2023-2026. All rights reserved.
Design and specifications are subject to change without notice.
Model number: TSX-306A
MWPCT0012EAA 2026-04 Published in Japan

The clinical results described in this paper are the experience of the authors.
Results may vary due to clinical setting, patient presentation and other factors.

Development and manufacturing functions of Canon Medical Systems Corporation have been transferred to CANON INC.
This document was created prior to the name change and therefore the former company name may still be referred to within the document.

CANON MEDICAL GROUP

Made For life