

Tuberculous Meningitis

Abstract

We are often mistaken that tuberculosis is the disease of the 18th and 19th centuries. Unfortunately tuberculosis remains the biggest killer, surpassing even HIV and malaria. Nevertheless the involvement of central nervous system damage is rare. Let's see how to recognize it.

Cerebro-meningeal involvement is one of the serious forms of tuberculosis. Cerebro-meningeal tuberculosis is rare in developed countries. MRI allows detection of small lesions and their location.

Tuberculosis remains a common disease worldwide (Figure 1). After a period of decline, its incidence is growing again, and resistant forms develop. It usually occurs in the young adult, with a majority of cases before the age of 30. It is rare in developed countries but accounts from 10 to 30% of intracranial mass lesions in developing countries. Only 2-5% of tuberculous patients have central nervous system damage.

The involvement of the central nervous system is always secondary, the primary focus remains latent (pulmonary, but also abdominal or genitourinary). The lesions begin as a conglomerate of micro-granulomas in an encephalitis

zone, and they tend to form mature tuberculoma, first non-inflammatory, followed by central caseous necrosis (a form of necrosis specific to tuberculosis, characterized by the transformation of the cells that are at the center of the tuber). MRI is a sensitive tool for the detection of early small lesions, as well as possible encephalitic foci and allows a better detection of lesions thanks to its multiplanar imaging.

Complications

- Tub meningitis
- Hydrocephalus (neurological pathology)
- Hemiplegia (paralysis)
- Consciousness disorders
- Dysarthria (motor speech disorder caused by brain damage)

Possible treatments

- Anti-bacillary treatment associated with corticosteroid therapy with a good clinical and radiological outcome
- Anti-inflammatory treatment
- Symptomatic treatment

In Vitrea

Brain Tumor module within Olea Sphere® provides quick access to all perfusion maps, ADC and anatomical exam sequences. Perfusion images with contrast agent injection (Perfusion module) or without (ASL module) can be very useful for detecting abnormalities. The combined analysis of the rBV, ADC and K (Figure 2) of the enhanced part and the remote portion of the suspect zone makes it possible to rule out the differential diagnosis of glial tumor.

TUBERCULOSIS

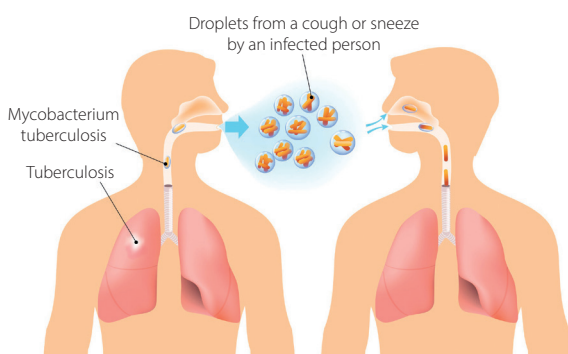


Figure 1

The fusion of anatomical images and calculated maps improves the visualization and the relevance of the analysis of the pathological zone. Olea Vision™ module provides good visualization and analysis of small lesions (Figure 3).

The automatic display of the mid-sagittal plane makes it easier to compare with the contralateral side as well as to assess the subfalcine herniation.

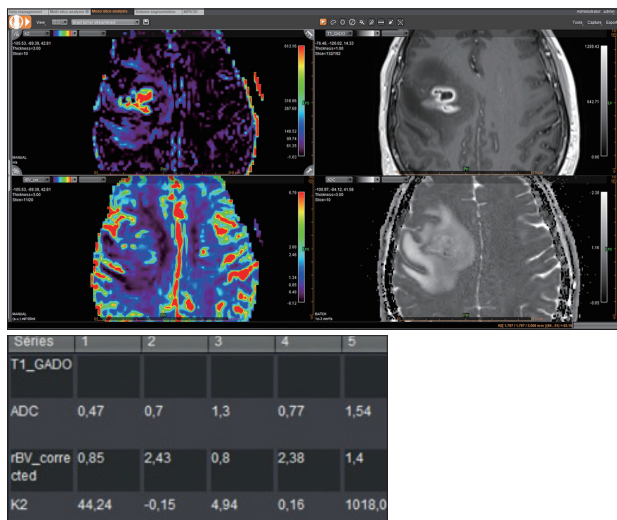


Figure 2

Addition

DTI analysis helps to investigate the impact on nerve fibers. Spectroscopy is used for coline peak, creatine and lipid indicators of necrosis evaluation.

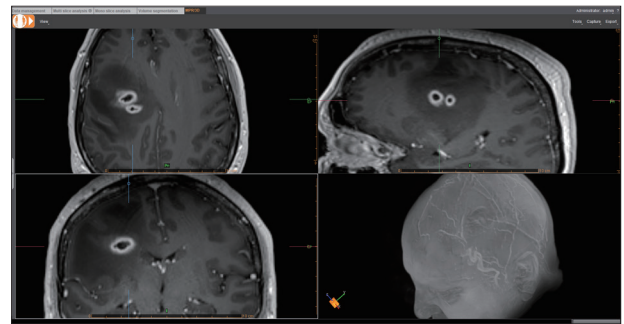


Figure 3

CANON MEDICAL SYSTEMS CORPORATION
<https://global.medical.canon>

©Canon Medical Systems Corporation 2019-2021. All rights reserved.
 Design and specifications are subject to change without notice.
 MOIH0010EAA 2021-10 CMSC/Produced in Japan

Canon Medical Systems Corporation meets internationally recognized standards for Quality Management System ISO 9001, ISO 13485. Canon Medical Systems Corporation meets the Environmental Management System standard ISO 14001.

Made for Life is a trademark of Canon Medical Systems Corporation.
 Olea Sphere and Olea Vision are either registered trademarks or trademarks of Olea Medical S.A.S.
 This document may include trademarks or registered trademarks of their respective owners.

The results in this document are the findings of the author.
 Clinical outcomes may vary dependent upon clinical use and environment.

Made For life