

Glioblastoma

Abstract

Glioblastoma accounts for 15 to 20% of brain tumors. Its average survival is 18 months. 70% of glioblastomas occur between 45 and 70 years old. Glioblastomas predominate in men in a ratio of 1.5 to 1.8 / 1¹.

Glioblastoma is the most common brain tumor in adults (Figure 1) with an annual incidence of 3.0 to 3.6 cases per 100,000, corresponding to 240,000 new cases per year worldwide. Ranked grade IV glioma by the World Health Organization (WHO), its prognosis is poor, with a 5-year survival rate of 3%.

Nearly 90% of glioblastomas are primary tumors (de novo), characterized by a short clinical history (<3 months) with no precedent of glioma; the remaining 10% are secondary to the anaplastic transformation of an infiltrating Grade II or III glioma.

Histologically, we find a neo-angiogenesis, known to be an important element of aggressiveness of these tumors, reflecting their degree of malignancy. These new vessels are abnormal, fragile and permeable, contributing to peritumoral edema and increased risk of bleeding.

Imaging plays a central role in the diagnosis and follow-

up of glioblastomas. In 1990, Macdonald introduced the first classification, revised and now improved by the RANO criteria ("Revised Assessment in Neuro-Oncology") in 2010.

Complications

- Hemorrhage
- Hydrocephalus
- Cerebral commitment
 - Temporal commitment
 - Extension to cerebellar tonsils in the occipital fossa
- Tumor meningitis
- Thromboembolic pathology
- Infectious complications

Possible treatments

- Surgery, including a more or less complete excision of the tumor
- In situ chemotherapy with Carmustine implants (Gliadel®)
- Radiotherapy 4 to 6 weeks after surgery
- Association of Nitrosourea chemotherapy such as Temozolomide (Temodal®)
- Second-line chemotherapy with VEGF inhibitors, Bevacizumab (Avastin®)
- New type of immunotherapy-based treatment

In Vitrea

The Perfusion (DSC) and Diffusion plugins can be used in addition to conventional sequences to assess brain tumors.

In this Glioblastoma case (Figure 2) we note an increase of rCBV to 7.57 mL/100mL at the level of the fleshy tissue of the tumor, 8 times higher than the healthy contralateral value. The presence of necrosis being noticeable, a T1 perfusion (DCE) was also added to the protocol, increased AUC (Area Under the Curve) and Ktrans values can be found.

A texture analysis with the Entropy study makes it possible to assess the spectrum of singularities of the

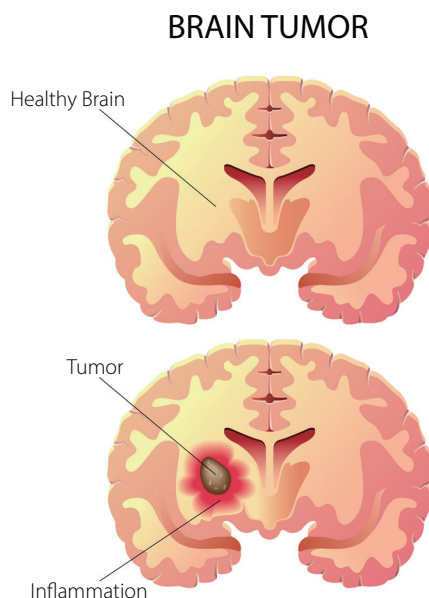


Figure 1

image of the different levels of gray (Figure 2).

The longitudinal analysis plugin makes it possible to compare all sequences and parametric maps over time using a suitable registration. We can follow, in this case, the evolution of rCBV, already increasing on the first examination in March, without any contrast enhancement on T1 post gadolinium (Figure 3).

Addition

rCBV "relative Cerebral Blood Volume" is a good marker of tumor grade and useful during patient monitoring

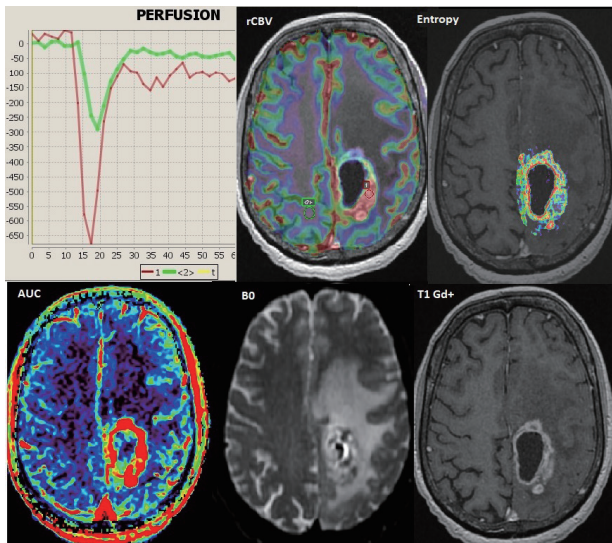


Figure 2

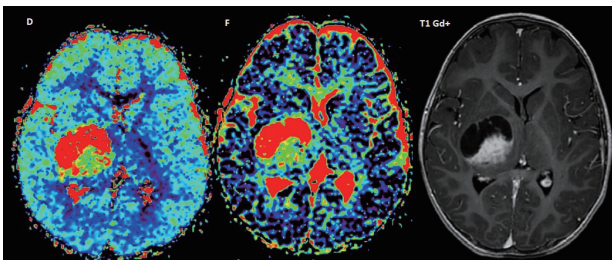


Figure 4

to discriminate recurrence from pseudo progression. The volumetric study of tumors seems to be robust and promising, compared to two-dimensional measurements recommended today in the follow-up (Figure 3). IVIM (intravoxel incoherent motion) parameters, calculated using diffusion imaging, are new useful biomarkers in the analysis of brain tumors (Figure 4).

References

1. Baldi I, Huchet A, Bauchet L, Loiseau H. [Epidemiology of glioblastoma]. Neurochirurgie 2010;56:433-40

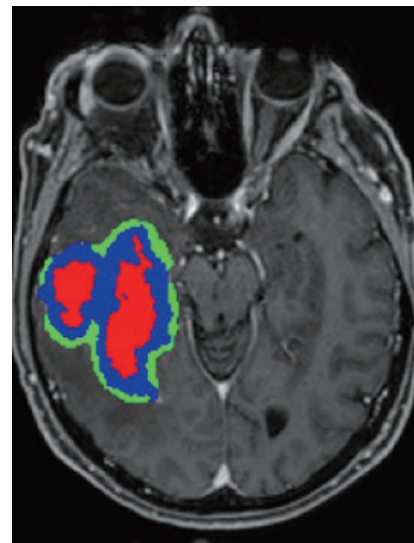


Figure 3

CANON MEDICAL SYSTEMS CORPORATION
<https://global.medical.canon>

©Canon Medical Systems Corporation 2019-2021. All rights reserved.
Design and specifications are subject to change without notice.
MOIH10006EAA 2021-10 CMSC/Produced in Japan

Canon Medical Systems Corporation meets internationally recognized standards for Quality Management System ISO 9001, ISO 13485. Canon Medical Systems Corporation meets the Environmental Management System standard ISO 14001.

Made for Life is a trademark of Canon Medical Systems Corporation.
Gliadel is a registered trademark of Eisai Inc.
Temozar is a registered trademark of Merck Sharp & Dohme Corp., a subsidiary of Merck & Co., Inc.
Avastin is a registered trademark of Genentech, Inc. (USA).
This document may include trademarks or registered trademarks of their respective owners.

The results in this document are the findings of the author.
Clinical outcomes may vary dependent upon clinical use and environment.

Made For life